

Successful Management of Cervical Ectopic Pregnancy: A Case Report

Laya Shirinzadeh (MD)¹, Amir Hosein Jafarian (MD)², Behrouz Davachi (MD)³, Leila Mousavi Seresht (MD)⁴, Helena Azimi (MD)⁴, Samaneh Akbarzadeh (MD)⁵, Yasaman Nikooiyan (MD)⁶, Zohreh Yousefi (MD)^{7*}

¹ Fellow, Gynecologic Oncology, Department of Obstetrics and Gynecology, Faculty of Medicine, Mashhad University of Medical Sciences, Mashhad, Iran

² Associate Professor, Department of Pathology, Faculty of Medicine, Mashhad University of Medical Sciences, Mashhad, Iran

³ Associate Professor, Department of Radiology, School of Medicine, Ghaem Hospital, Mashhad University of Medical Sciences, Mashhad, Iran

⁴ Fellow, Gynecologic Oncology, Department of Obstetrics and Gynecology, Faculty of Medicine, Mashhad University of Medical Sciences, Mashhad, Iran

⁵ Resident, Department of Obstetrics and Gynecology, Faculty of Medicine, Mashhad University of Medical Sciences, Mashhad, Iran

⁶ Medical Student, Faculty of Medicine, Mashhad University of Medical Sciences, Mashhad, Iran

⁷ Professor, Department of Obstetrics and Gynecology, Fellowship of Gynecologic Oncology, Faculty of Medicine, Mashhad University of Medical Sciences, Mashhad, Iran

ARTICLE INFO

ABSTRACT

Article type:

Case report

Article History:

Received: 11-Oct-2018

Accepted: 24-Dec-2018

Key words:

Conservative management

Ectopic pregnancy

Methotrexate

Background: Cervical ectopic pregnancy is a rare condition with an incidence of less than 0.1% in all ectopic pregnancies. This life-threatening condition is associated with a high morbidity and mortality rates. Recently, the recommended protocol for the treatment of cervical ectopic pregnancy is fertility preservation rather than invasive surgery and hysterectomy. The aim of this report was to introduce a case of successful management of cervical ectopic pregnancy.

Case report: A 31-year-old woman was presented with her third pregnancy with a history of one cesarean section and spontaneous abortion. She was admitted to an academic hospital with vaginal bleeding following 10 weeks of amenorrhea. Based on transvaginal ultrasound, a live fetus of about nine weeks was reported, located in the cervical canal. The β -subunit of human chorionic gonadotropin (β hCG) titer was reported as 108000 mIU/m. Cervical pregnancy diagnosis was consistent. In order to preserve fertility based on the patient's hemodynamic status, medical treatment and surgical intervention, including methotrexate and then intravaginal ligation of cervical branches of uterine arteries, and subsequently cervical tampon was successfully performed.

Conclusion: The early detection and accurate diagnosis of cervical ectopic pregnancy using ultrasound and serial β hCG titer can be a valuable approach. Appropriate and conservative management has decreased the morbidity rate and preserved the ongoing fertility in the affected patients.

► Please cite this paper as:

Shirinzadeh L, Jafarian AH, Davachi B, Mousavi Seresht L, Azimi H, Akbarzadeh S, Nikooiyan Y, Yousefi Z. Successful Management of Cervical Ectopic Pregnancy: A Case Report. Journal of Midwifery and Reproductive Health. 2020; 8(1): 2208-2212. DOI: 10.22038/jmrh.2019.35481.1385

Introduction

Ectopic pregnancy is a major complication of pregnancy in the first trimester. Cervical ectopic pregnancy (i.e., the implantation of gestational sac in the cervical canal) is a serious threat to a pregnant woman and her fetus that is associated with high mortality and morbidity rates (1). This type of ectopic pregnancy is an extremely infrequent condition accounting for less than

1% of all ectopic pregnancies (2). In the UK, 11,000 ectopic pregnancies are diagnosed each year. Most of them occur in the fallopian tubes; however, three to five cases per 100 ectopic pregnancies happen in other sites, including the cervix or abdomen.

Currently, the majority of women with cervical ectopic pregnancy die from the

* Corresponding author: Zohreh Yousefi, Professor, Department of Obstetrics and Gynecology, Fellowship of Gynecologic Oncology, Faculty of Medicine, Mashhad University of Medical Sciences, Mashhad, Iran. Tel: +985138412477; Email: Yousefiz@mums.ac, info@zohreyousefi.com

condition. Six maternal mortalities were reported between 2006 and 2008 (3). In a study carried out by Andrés (2012), the incidence of cervical ectopic pregnancy was reported as 1 in 18,000 pregnancies (4). Risk factors of cervical pregnancy include previous endometrial curettage, use of intrauterine devices, any manipulations and procedures performed on the cervix, such as dilatation of the cervix with a device. In addition, previous cesarean section is considered to be as a potential risk factor. However, the prevalence of cervical ectopic pregnancy has increased with assisted reproductive technologies (5).

It should be remembered that cervical pregnancy is very dangerous. If the risk of massive hemorrhage is not considered and the patient is not properly treated, it remains to be catastrophic and life-threatening. However, in the majority of women with an ectopic pregnancy, the risk factor is not clear (6). The diagnosis of cervical ectopic pregnancy depends on the patient's symptoms, β -subunit of human chorionic gonadotropin (β hCG) titer, and ultrasound findings. In the past, cervical pregnancies were treated with hysterectomy due to associated significant hemorrhage (7). Cervical pregnancy is a rare type of ectopic pregnancy. Most of the patients suffer from massive vaginal bleeding. Detection of the gestational sac or placental tissue within the cervix and hourglass view in transvaginal ultrasound are evidences of cervical ectopic pregnancy (8). The most common symptom of this type of pregnancy is spotting. One third of the patients have reported mild discomfort in their lower abdomen. In vaginal examination, endo-cervix may be open or closed. Our patient was diagnosed with transvaginal ultrasound and clinical examination.(9)

In recent years, with the improvements in ultrasound resolution and availability, the early diagnosis of these pregnancies has become possible. Therefore, conservative management, such as fertility preservation, has been considered which led to reduced mortality rates (10). According to the results of a study conducted by Ruano et al. (2006), the diagnosis of cervical ectopic pregnancy with conventional two-dimensional ultrasound was successfully performed. In addition, he was able to treat the patient with intramuscular injections of

Methotrexate (MTX) without any complications (11).

In another study carried out by Hirakawa et al. (2007), it was reported that 5% of the cases with cervical pregnancy required blood transfusions due to massive vaginal bleeding and only 1% of the patients needed a hysterectomy (12). Proper treatment and the early detection of cervical ectopic pregnancy resulted in fewer complications. In this report, we presented the successful management of a case of cervical ectopic pregnancy.

Case report

A 31-year-old woman with a history of one cesarean section and spontaneous abortion was referred to the oncology department of an academic hospital in Mashhad University of Medical Sciences in 2017. This report was written with the patient's informed consent. The case suffered from light spotting following 10 weeks of amenorrhea. In physical examinations, there was no abdominal tenderness. Pelvic examination showed light spotting, cervical motion tenderness, a balloon shaped cervical canal, and intact external os of the cervix. Transvaginal ultrasound reported a live fetus of about nine weeks located in the cervical area (Figure 1). At the same time, β hCG titer was 108,000 mIU/ml.

The patient had a stable hemodynamic state. She was admitted to the hospital with a diagnosis of cervical ectopic pregnancy. In an attempt to preserve fertility, conservative management was planned. Based on multidisciplinary team decision-making, 50 mg/m² of intramuscular MTX was injected as a single dose. Unexpectedly, on the tenth day after the treatment, one episode of massive vaginal bleeding happened resulted in blood transfusion. Moreover, transvaginal ligation of cervical branches of the uterine arteries was performed.

In addition, evacuation suction curettage was carried out. Subsequently, Foley catheter tamponade was placed inside the cervix for 12 h. The pathology report of the specimen was decidual tissue and chorionic villi adjacent to endocervical tissue that was consistent with the diagnosis of cervical ectopic pregnancy (Figure 2).

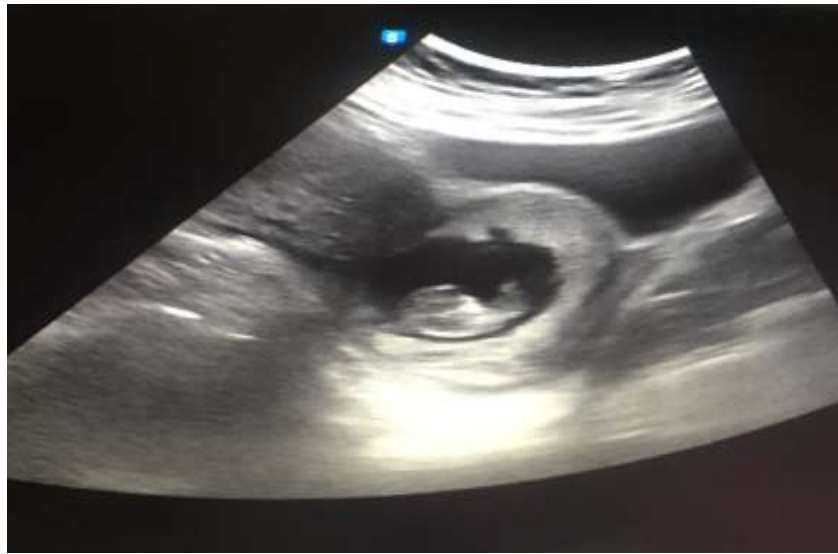

Figure 1. Nine weeks of pregnancy in cervical area with fetal heart rate

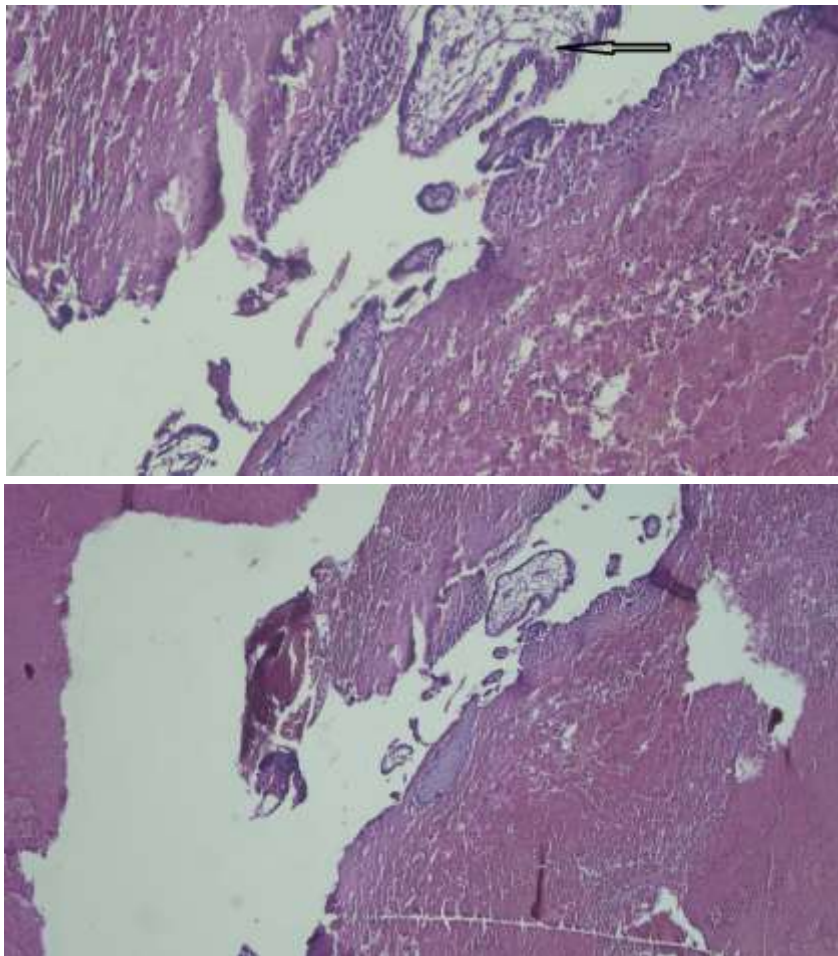


Figure 2. Product of decidual tissue and chorionic villi with adjacent endocervical tissue consistent with the diagnosis of cervical ectopic pregnancy

Based on the satisfactory general condition of the patient, she was followed by repeating the serum β HCG levels. After two consequent weeks, β HCG titer returned to a normal level (4 mIU/ml). Moreover, the ultrasound report was normal. At the moment, the patient is in a good condition with no signs or symptom of the disease.

Discussion

With regard to the lack of a standard approach to cervical ectopic pregnancy medical or surgical approaches are performed to maintain hemodynamic state and fertility preservation. In this case, the early diagnosis of cervical ectopic pregnancy was based on clinical signs and symptoms. However, ultrasound was very helpful in this regard. In addition, successful scientific approach to cervical pregnancy was performed according to the most acceptable guidelines. The combination of evacuation suction curettage, followed by MTX injection and ligation of arteries led to this case's survival.

The only risk factor of this patient for cervical ectopic pregnancy was considered cesarean section. However, in the initial presentation, the symptoms were unremarkable. Based on Surampudi K et al., a case report of correct diagnosis could reduce life-threatening events in these patients (6). Samal S et al. (2015) reported the successful management of a 29-year-old, G₂L₁ woman with the diagnosis of a live seven-week cervical ectopic pregnancy. The case was treated with the combination of intra-amniotic potassium chloride and MTX, followed by suction curettage (13).

In fact, fetal death with potassium and the effect of MTX on pregnancy will result in a safe and accurate method of terminating the gestational process performed in this patient. However, in this case, only MTX was used for the patient. Kadija (2016) treated a 12-week live fetus in the isthmus-cervical part with the combination of curettage and cervical tamponade following by the administration of systemic MTX (14). It seems that due to the longer gestational age, this method was a good choice. Similar to the present case, a combination of multimodality procedures was successfully performed. In spite of evacuation

curettage, due to massive and sudden vaginal bleeding, the arterial branches ligation of the cervix was necessary on both sides.

Traditionally, hysterectomy was the choice of treatment; however, in recent years conservative management is mostly recommended and the treatment trend is towards fertility preservation. In this case, the researchers tailored to alternative management in order to preserve fertility. Uterine arteries embolization and hemostatic vaginal sutures of the cervix are safe and considered as reasonable approaches. In the present case, significant vaginal bleeding minimized the following ligation of arterial branches (15).

Medical treatments, such as MTX has been proposed in recent years. A good candidate for the prescription of MTX has the characteristics as it follows: hemodynamic stability, low serum β -hCG (ideally less than 1500 IU/ml with the possibility of up to 5000 IU/ml), no fetal cardiac activity on ultrasound scan, certainty about the absence of intrauterine pregnancy, and willingness to attend follow-ups (16). The MTX administration is systematic, intravenous, local, and intracervical or intra-amniotic in case of fetal waste (17). Combination therapy with the intra-amniotic injection of MTX has shown to increase the chance of successful treatment.

However, the cases with the gestational age of more than nine weeks, β -hCG levels higher than 10,000 IU/ml, crown-rump length higher than 10 mm, and fetal cardiac activity were shown to be associated with a higher risk of primary failure of the treatment that is similar to the present case (15). This case illustrates an important issue that is multimodality management regarding fertility preservation. Indeed, accurate diagnosis, appropriate conservative management of cervical ectopic pregnancy, and fertility preservation are presented to be suitable for these patients.

Conclusion

The early diagnosis of cervical ectopic pregnancy using ultrasound and the utilization of conservative management has decreased morbidity rate and preserved the ongoing fertility in the affected cases. The prevention of the cesarean section without indications or any unnecessary surgical interventions can reduce

the risk of ectopic pregnancy.

Acknowledgments

Thanks for the cooperation of the personnel of academic Hospital in Ghaem Mashhad.

Conflicts of Interest

The authors declare no conflicts of interest.

References

- Moragianni VA, Hamar BD, McArdle C, Ryley DA. Management of a cervical heterotopic pregnancy presenting with first-trimester bleeding: case report and review of the literature. *Fertility and Sterility*. 2012; 98(1):89-94.
- Kochi K, Hidaka T, Yasoshima K, Yoneda K, Arai K, Arai T. Cervical pregnancy: a report of four cases. *The Journal of Obstetrics and Gynaecology Research*. 2014; 40(2):603-606.
- Diagnosis and Management of Ectopic Pregnancy-RCOG. Available at: URL: <https://www.rcog.org.uk/en/guidelines-research-services/guidelines/gtg21>; 2016
- Andrés MP, Campillos JM, Lapresta M, Lahoz I, Crespo R, Tobajas J. Management of ectopic pregnancies with poor prognosis through ultrasound guided intrasacular injection of methotrexate, series of 14 cases. *Archives of Gynecology and Obstetrics*. 2012; 285(2):529-533.
- Chrestiana D, Cheng AB, Panebianco NL, Dean AJ. Pitfalls in cervical ectopic pregnancy diagnosis by emergency physicians using bedside ultrasonography. *The American Journal of Emergency Medicine*. 2014; 32(4):397.e1-3.
- Surampudi K. A case of cervical ectopic pregnancy: successful therapy with methotrexate. *Journal of Obstetrics and Gynaecology of India*. 2012; 62(Suppl 1):1-3.
- Taylor JE, Yalcinkaya TM, Akar ME. Successful conservative management of cervical ectopic pregnancy: a case series. *Archives of Gynecology and Obstetrics*. 2011; 283(6):1215-1217.
- Leeman LM, Wendland CL. Cervical ectopic pregnancy. Diagnosis with endovaginal ultrasound examination and successful treatment with methotrexate. *Archives of Family Medicine*. 2000; 9(1):72-77.
- Ruano R, Reya F, Picone O, Chopin N, Pereira PP, Benachi A, et al. Three-dimensional ultrasonographic diagnosis of a cervical pregnancy. *Clinics*. 2006; 61(4):355-358.
- Munoz JL, Kalan A, Singh K. Second trimester cervical ectopic pregnancy and hemorrhage: a case report and review of the literature. *Case Reports in Obstetrics and Gynecology*. 2018; 2018:1-3.
- Pourali L, Ayati S, Moeendarbari S, Mirzamarjani F, Ayati E. A successful treatment of cervical ectopic pregnancy with multidose methotrexate. *Current Women's Health Reviews*. 2016; 12(1):71-73.
- Hirakawa M, Tajima T, Yoshimitsu K, Irie H, Ishigami K, Yahata H, et al. Uterine artery embolization along with the administration of methotrexate for cervical ectopic pregnancy: technical and clinical outcomes. *American Journal of Roentgenology*. 2009; 192(6):1601-1607.
- Samal S, Ghose S, Pallavee P, Porkkodi P. Successful management of live cervical ectopic pregnancy: a case report. *Journal of Clinical and Diagnostic Research*. 2015; 9(12):QD03-4.
- Kadija S, Stefanovic A, Jeremic K, Radojevic M, Cerovic-Popovic R, Srbnovic M, et al. Successful conservative treatment of a cervical ectopic pregnancy at 13 weeks. *Clinical Experimental Obstetrics & Gynecology*. 2016; 43(2):291-293.
- Yamagami T, Yoshimatsu R, Matsumoto T, Anzai H, Yoshizawa M, Fukui Y, et al. Fertility after uterine artery embolization: investigation using a sheep model. *Reproductive Sciences*. 2010; 17(4):350-357.
- Pantelis A, Daniilidis A, Dinas K. Conservative treatment of a 7 week cervical ectopic pregnancy after intra-uterine insemination. *Hippokratia*. 2013; 17(1):95.
- Weibel HS, Alserri A, Reinhold C, Tulandi T. Multidose methotrexate treatment of cervical pregnancy. *Journal of Obstetrics and Gynaecology Canada*. 2012; 34(4):359-362.