

## Incisional Endometriosis: A Rare Case of Painful Scar

Nalini Sharma (MS)<sup>1\*</sup>, Thiek J Lalnunem (MS)<sup>2</sup>, Khonglah Yookerine (MD)<sup>3</sup>, Ahanthem Santa Singh (MD)<sup>4</sup>

<sup>1</sup> Assistant Professor, Department of Obstetrics and Gynecology, North Eastern Indira Gandhi Regional Institute of Health and Medical Sciences, Shillong, Meghalaya

<sup>2</sup> Senior Resident, Department of Obstetrics and Gynecology, North Eastern Indira Gandhi Regional Institute of Health and Medical Sciences, Shillong, Meghalaya

<sup>3</sup> Associate Professor, Department of Pathology, North Eastern Indira Gandhi Regional Institute of Health and Medical Sciences, Shillong, Meghalaya

<sup>4</sup> DNB, Professor and Head, Department of Obstetrics and Gynecology, North Eastern Indira Gandhi Regional Institute of Health and Medical Sciences, Shillong, Meghalaya

### ARTICLE INFO

### ABSTRACT

*Article type:*  
Case report

*Article History:*

Received: 13-Feb-2016

Accepted: 25-Nov-2016

*Key words:*

Caesarean section

Endometriosis

Extra pelvic

Scar

Scar endometriosis is a rare form of extra-pelvic endometriosis that can occur after surgery involving the uterus. Direct mechanical implantation seems to be the most conceivable theory for scar endometriosis. Patient usually presents with lump and pain at surgical site. Often the diagnosis of endometriosis is not suggested until histology has been performed. We hereby present a case of scar endometriosis diagnosed preoperatively by fine-needle aspiration cytology. Scar endometriosis is a rare cause of painful scar; therefore, high index of suspicion is suggested in clinching the diagnosis. The recommended treatment is wide surgical excision with at least 1 cm margin on all sides. While performing lower segment caesarean section some preventive measures should be taken to prevent its occurrence. Histopathological examination is mandatory, as there is rare possibility of malignant transformation. Follow-up is advisable to diagnose recurrence.

► Please cite this paper as:

Nalini S, Lalnunem TJ, Yookerine Kh, Santa Singh A. Incisional Endometriosis: A Rare Case of Painful Scar. Journal of Midwifery and Reproductive Health. 2017; 5(2):927-929. DOI: 10.22038/jmrh.2017.8212

## Introduction

Endometriosis is characterized by the presence of endometrial glands and stroma outside the uterus (1). The most common sites are the ovaries, pouch of Douglas, and uterosacral ligaments in the pelvis. Extra-pelvic endometriosis is uncommon only accounting for 1% of total cases. It may affect the lungs, kidneys, bladder, bowel, omentum, nervous system, appendix, and umbilicus (2). The most common extra pelvic form of endometriosis is cutaneous endometriosis mainly in scars following obstetrics and gynecological surgeries, such as caesarean section, hysterotomy, hysterectomy, puerperal ligation, salpingectomy, episiotomy, laparoscopic surgery, uterine suspension, inguinal herniorrhaphy, Bartholin cyst excision, laparotomy, abdominoplasty, and amniocentesis (2-4). Scar endometriosis presents clinically as a painful, palpable subcutaneous mass with exaggeration during menses. Inadvertent

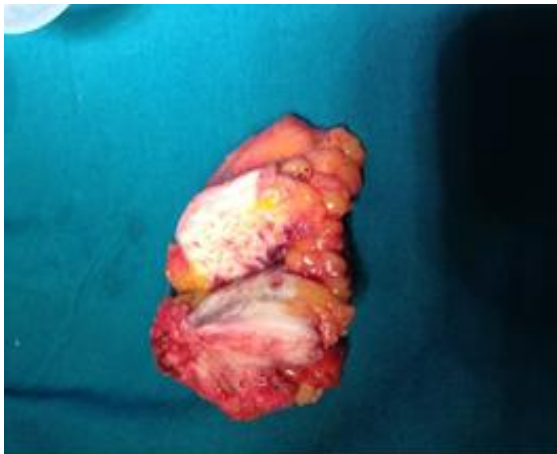implantation during surgery is the most conceivable theory for incisional endometriosis. Histopathological examination is the gold standard for diagnosis. We present a case of scar endometriosis presenting within one year of lower segment caesarean section (LSCS).

## Case report

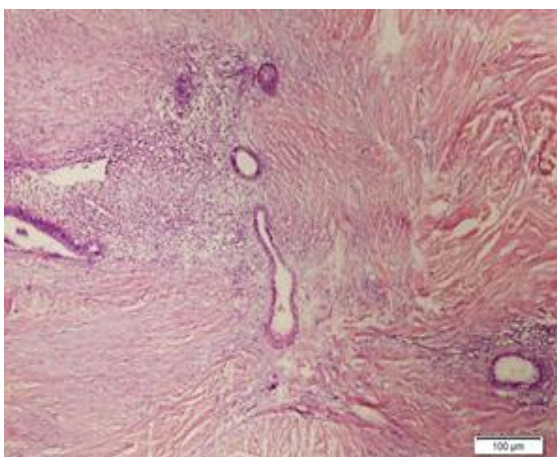
A 37-year-old (para 2, living 2) presented to the hospital with complaint of pain at the site of caesarean scar during menstruation associated with swelling at the same site since the last five years. The swelling increases during menses. She delivered her last child six years before by LSCS. There was no history of endometriosis. General and systemic examination of the patient revealed no abnormalities. On local examination, suprapubic transverse scar was seen, but there was no visible swelling along the scar. A small lump measuring approximately 3 × 3 cm was felt at the edge of the caesarean scar

\* Corresponding author: Sharma Nalini, Department of Obstetrics and Gynecology, North Eastern Indira Gandhi Regional Institute of Health and Medical Sciences, Shillong, Meghalaya. Tel: 9774066673; Email: Nalinisharma100@rediffmail.com

towards the right side. The swelling was firm in consistency, fixed to the surrounding tissue, which was non-tender. Per speculum and bimanual examination revealed no abnormality. Ultrasonography showed right-sided, surface occupying lesion in the subcutaneous plane measuring 2.5 × 2.2 cm with an impression of scar endometriosis with no evidence of pelvic endometriosis. Fine needle aspiration cytology of the swelling revealed scar endometriosis. The mass (Figure 1) was excised completely without any complication and sent for histopathological examination, which revealed scar endometriosis (Figure 2).



**Figure 1.** Cut section of mass of 5\*5\*3.5 cm showing fibro fatty tissue



**Figure 2.** 10x magnification showing endometrial gland and stroma in the background of dense fibrocollagenous tissue

## Discussion

Scar endometriosis is a rare cause of painful

surgical scar in women of reproductive age. It usually presents after obstetrical and gynecological surgeries.

Incidence rate of incisional endometriosis following hysterotomy is 1.08-2%, whereas after caesarean section, the incidence rate reduces to 0.03-0.4% (1, 2). Higher incidence after hysterotomy could be explained by higher pluripotential capability of early decidua, which can result in cellular replication forming endometriomas (2). The most common site of incisional endometriosis is near a Pfannenstiel incision. This is possibly related to the wider dissection of the tissue planes when compared to vertical midline incision.

Inadvertent implantation during surgery is the most explainable theory for incisional endometriosis. This implantation is subsequently stimulated by estrogen. Another theory is mainly based on the fact that peritoneal mesothelial cells undergo metaplasia to endometriosis. Coelomic metaplasia theory explains cases of spontaneous endometriosis when there is no history of any surgery. It is observed that endometrioma can occur in the umbilicus even without predecessor surgery (5). A painful mass near scar with symptoms related to menstruation is pathognomonic of this condition, but only 20% of patients present with typical presentation. Therefore, it is often misdiagnosed as incisional hernia, suture granuloma, lipoma, abscess, cyst hematoma, or foreign body (3). Often the diagnosis of endometriosis is not made until the histology has been performed. The presence of any two of the three components (i.e., endometrial glands, stromal cells, and hemosiderin laden macrophages) has been used for the cytological diagnosis of endometriosis.

Correct preoperative diagnosis is attained only in 20-50% of cases. Recently, ultrasound examination along with Doppler study with clinical data is recommended for preoperative diagnosis as it is widely available with lower cost (1). Fine-needle aspiration cytology is one of the diagnostic methods as in the present case, but possibility of incisional hernia and reimplantation of potential malignant cells should also be taken into consideration, as well. Magnetic resonance imaging and computed tomography scan have almost similar sensitivity and specificity of 90-92% and 91-98%, respectively.

These modalities can be used to know the extent and depth of lesion for presurgical mapping (6).

Another study observed that 25% of the patients who develop incisional endometriosis have concomitant pelvic endometriosis.<sup>7</sup> However, it is not advisable to perform simultaneous laparoscopy to diagnose coexisting pelvic endometriosis while performing a local excision. Medical management with oral contraceptive pills, as well as progestogen and gonadotrophin-releasing hormone analogues provide symptomatic improvement, but recurrence is common after cessation of therapy.

Recommended treatment is wide surgical excision with at least 1 cm margin on all sides and patch grafting of the facial defect, if required. Recurrence is always anticipated in all cases of endometriosis, which should be explained to patients before they undergo surgery. Patients should be followed-up for recurrence. Malignancies in incisional endometriosis are rare, occurring in 0.31% of cases. The most common histological type is clear cell carcinoma (8). Malignancy should be suspected in frequent recurrence or in fast-growing, large endometriosis (9).

With the increasing rate of LSCS, one can expect increase in the number of cases of scar endometriosis. Use of separate needles and mops for the uterine cavity and other tissues, closure of the visceral and parietal peritoneum, and thorough cleaning and irrigation of abdominal wall wound before closure are the recommended steps to prevent scar endometriosis (2).

Because of its scarcity and sometimes late presentation, high index of suspicion should be kept for cases with previous history of pelvic surgery presenting with painful swelling of abdominal scar. The treatment of choice is wide surgical excision. Histopathological examination is necessary, as there is rare possibility of malignant transformation. Follow-up is advisable to diagnose recurrence.

## Conclusion

Scar endometriosis is a rare cause of painful surgical scar in women of reproductive age. High index of suspicion should be considered for cases with previous history of pelvic surgery

presenting with painful swelling of abdominal scars. The treatment of choice is wide surgical excision. Histopathological examination should be done to rule out rare possibility of malignant transformation. Follow-up is recommended to diagnose recurrence.

## Acknowledgments

None declared.

## Conflicts of interest

None declared.

## References

1. Francica G, Giardiello C, Angelone G, Criastaino S, Finelli R, Tramontano G. Abdominal wall endometriomas near cesarean delivery scars sonographic and color Doppler findings in a series of 12 patients. *Journal of Ultrasound in Medicine*. 2000; 22(10):1041-1047.
2. Goel P, Sood SS, Dalal A. Cesarean scar endometriosis-Report of two cases. *Indian Journal of Medical Sciences* Indian J Med Sci. 2005; 59(11):495-498.
3. Sengul I, Sengul D, Kahyaoglu S, Kahyaoglu I. Incisional endometriosis: a report of 3 cases. *Canadian Journal of Surgery*. 2009; 52(2):444-445.
4. DO JC, Nicole Durie MD. Scar endometriosis-a rare cause for painful scar: a case report and review of the literature. *The Canadian Journal of Plastic Surgery*. 2010; 18(1):19-20.
5. Chatzikokkinou P, Thorfinn J, Angelidis IK, Papa G, Trevisan G. Spontaneous endometriosis in an umbilical skin lesion. *Acta Dermatovenerologica Alpina, Pannonica, et Adriatica*. 2009; 18(3):126-130.
6. Blanco RG, Parithivel VS, Shah AK, Gumbs MA, Schein M, Gerst PH. Abdominal wall endometriomas. *The American Journal of Surgery*. 2003; 185(6):596-598.
7. Wolf Y, Haddad R, Werbin N, Skornick Y, Kaplan O. Endometriosis in abdominal scars: a diagnostic pitfall. *The American Surgeon*. 1996; 62(12):1042-1044.
8. Achach T, Rammeh S, Trabelsi A, Ltaief R, Ben Abdelkrim S, Mokni M, et al. Clear cell adenocarcinoma arising from abdominal wall endometriosis. *Journal of Oncology*. 2008; 2008:1-3.
9. Surgent F, Baron M, Le Cornee JB, Scotté M, Mace P, Marpeau L. Malignant transformation of abdominal wall endometriosis: a new case report. *Journal of Gynecology, Obstetric and Biology of the Reproduction*. 2006; 35(2):186-190.