

Abdominal Compartment Syndrome after Cesarean Section: A Case Report

Nazanin Beheshtian (MD)¹, Samaneh Akbarzadeh (MD)¹, Bita Zargaran (MD)², Helena Azimi (MD)³, Amir Hossain Jafarian (MD)⁴, Zohreh Yousefi (MD)^{1*}, Akram Khalaati (MD)⁵

¹ Professor, Department of Obstetrics and Gynecology, Faculty of Medicine, Mashhad University of Medical Sciences, Mashhad, Iran

² General practitioner, Faculty of Medicine, Islamic Azad University, Mashhad Branch, Mashhad, Iran

³ Resident in Gynecologic Oncology Fellowship, Department of Obstetrics and Gynecology, Faculty of Medicine, Mashhad University of Medical Sciences, Mashhad, Iran

⁴ Associate professor, Department of Pathology, Faculty of Medicine, Mashhad University of Medical Sciences, Mashhad, Iran

⁵ Graduated, Faculty of Medicine, Mashhad University of Medical Sciences, Mashhad, Iran

ARTICLE INFO	ABSTRACT
<p><i>Article type:</i> Case report</p>	<p>Background: Abdominal compartment syndrome (ACS) after cesarean section (CS) is a rare event which is associated with an increased risk of morbidity and mortality. This complication may arise as a result of musculoskeletal trauma and fluid accumulation. The present report aimed to introduce a case of ACS after the cesarean section.</p> <p>Case report: We present the case of a 32-year old woman who developed abdominal compartment syndrome 4 days after the cesarean section. The patient's symptoms included severe abdominal distension, fever, decreased haemoglobin level despite normal blood pressure, and decreased urine output. Nasogastric/colonic decompression was not effective. Computed tomography (CT) scan demonstrated partial bowel obstruction. After an emergency decompressive laparotomy due to increased intra-abdominal pressure, the patient was diagnosed with ACS and rescued by supportive conservative treatment.</p> <p>Conclusion: ACS is a rare complication of CS; nonetheless, delayed diagnosis and intervention can cause irreversible damages. The physicians and midwives should be cautious about post caesarean signs and symptoms, including massive abdominal distention, pain, fever, difficulty breathing, and decreased urine output. Conservative therapeutic strategy and decompressive laparotomy is the gold standard treatment for this disease.</p>
<p><i>Article History:</i> Received: 10-Apr-2019 Accepted: 30-Aug-2019</p>	
<p><i>Key words:</i> Abdominal Compartment Syndrome Caesarean Section Intra-abdominal Pressure</p>	

► Please cite this paper as:

Beheshtian N, Akbarzadeh S, Zargaran B, Azimi H, Jafarian AH, Zohreh Yousefi Z, khalaati A Abdominal Compartment Syndrome after Cesarean Section: A Case Report. Journal of Midwifery and Reproductive Health. 2020; 8(4): 2512-2517. DOI: 10.22038/jmrh.2020.39012.1440

Introduction

Abdominal compartment syndrome (ACS) is defined as a sustained or repeated pathologic increase in IAP >12 mmHg (1). ACS has been indicated to occur frequently in patients admitted to intensive care units (ICU) and has been independently associated with mortality (1). In addition, this syndrome is accompanied by other organ dysfunction, especially intra-abdominal and pelvic component. The diagnosis of ACS is established when there is a sustained increased intra-abdominal pressure (IAP) in accordance with evidence of end-organ

dysfunction (2). The golden standard test for the diagnosis of ACS is intra-abdominal pressure along with intra-vesical pressure (2). The adverse effects of ACS on multiple organ systems include: renal, pulmonary, gastrointestinal, cardiovascular, musculoskeletal/integumentary (abdominal wall), and central nervous system (3). The definite management of ACS is based on optimal timing and staging of abdominal decompression and depends on the early identification of at-risk patients. In cases with intra-abdominal pressure

* Corresponding author: Zohreh Yousefi, Professor, Department of Obstetrics and Gynecology, Fellowship of Gynecologic Oncology, Faculty of Medicine, Mashhad University of Medical Sciences, Mashhad, Iran. Tel: 00985138412477. Email: yousefiz@mums.ac.ir

greater than 25 mm Hg and bladder pressure greater than 12 mm Hg, definitive diagnosis is ACS. It is of utmost importance to perform emergency surgical procedures in this condition. Untreated ACS cases can lead to high rates of morbidity and mortality (4). A few cases of this syndrome have been reported in the literature which developed after liver transplantation, ruptured aortic aneurysm and, retroperitoneal hematoma (5-7). To the best of our knowledge, no study has been conducted on this syndrome after cesarean section. With this background in mind, this report aimed to introduce a case of ACS after the cesarean section.

Case report

A-32-year old multiparous woman (3 vaginal delivery and one CS) with increased blood pressure (mean BP=140 mmHg) was hospitalized on 16th October 2018. She underwent a cesarean section due to the arrest of descent. During the surgery, uterine atony was observed, and severe hemorrhage happened. B-lynch suture, misoprostol administration, and conservative management were performed, according to the guidelines. In addition, two units of packed cells (PC) were transfused. After the surgery, the blood pressure remained normal; moreover, all laboratory tests related to preeclampsia were completely normal. After two days, the hemoglobin level decreased to 6.6 mg/dl for no obvious reason; therefore, 2 units of PC and 2 units of fresh frozen plasma (FFP) were transfused. Severe distension and fever emerged 4 days after the operation. Nasogastric/colonic decompression was not effective. Meropenem, Vancomycin, and Metronidazole were intravenously injected despite the absence of fever. Two days later, she referred to our academic hospital affiliated to Mashhad University of Medical Sciences due to severe abdominal distension and fever. On admission to the hospital, the patient was pale and ill. The primary vital signs included: heart rate (HR)=100 bpm, blood pressure (BP)=110/70 mmHg, and temperature=37.8°C. She had nausea without vomiting. The residue of the intra-abdominal drain was 60 cc and the incision site had a normal appearance. The blood electrolytes were assessed. 2 units of PC were transfused (haemoglobin: 7.3 mg/dl). The nasogastric tube had a little output. The chest X-

Ray was normal. According to abdominal ultrasonography, the uterine size was 130×330 mm with myometrium thickening, and gas was detected in the uterine cavity. The possible diagnosis was uterine atony and metritis. Abdominal flat X-ray and computed tomography (CT) scan demonstrated partial bowel obstruction only in small bowels. Emergency laparotomy was performed due to non-response to medical treatment. During laparotomy, enlarged soft uterus as equivocal 36 weeks of pregnancy was observed with a very pale appearance. Despite the reassessment of intracavity and removal of all stitches of CS, no reason to uterine distention was found. In addition, the left ovarian and fallopian tube were gangrened (Figure 1).

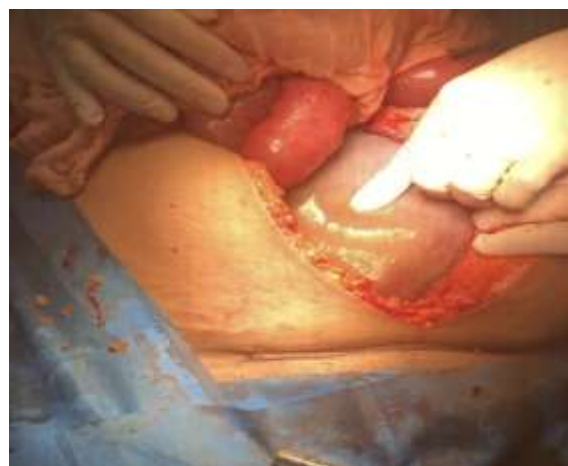

Figure 1. Laparotomy showing enlarged soft uterus as equivocal 36 weeks of pregnancy

The warm saline irrigation of the entire abdominal compartment was performed. Thereafter, she was admitted to ICU.

The patient's condition deteriorated the next day. Tachycardia, (heart rate (HR) =150 bpm), increased abdominal distension, and defecation failure were observed. High-risk Crisis Committee Team were consulted and second surgery as an emergency decompressive laparotomy was decided upon.

The surgeon's opinion was in favor of hysterectomy (Figure 2) along with frequent

evacuation of intestinal contents from the oesophagus to the rectum.

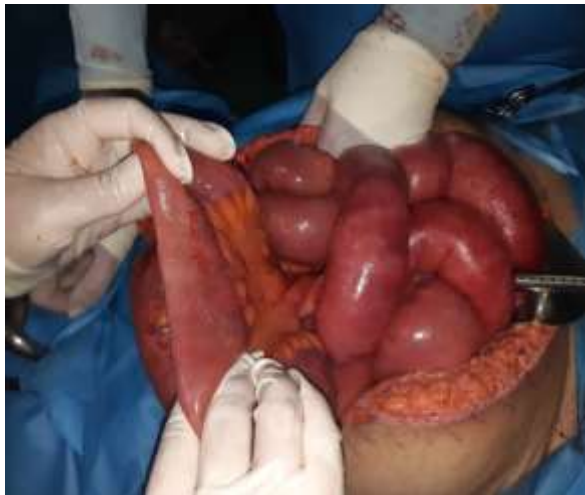

Figure 2. Appearance of severe bowel distension

This procedure was carried out by a general surgeon very gently and carefully and continued until feces and gas were completely removed from the intestines. Ultimately, the normal appearance of total intestines was observed (Figure 3).

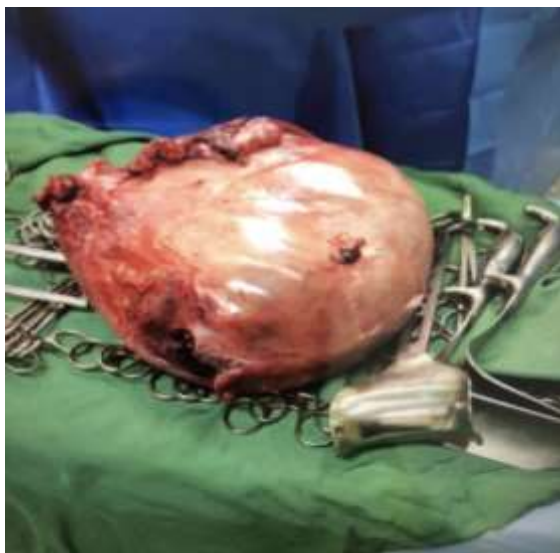

Figure 3. Macroscopic and microscopic patterns of hysterectomy

After the operation, intra-abdominal pressure, urinary bladder pressure, and central venous pressure (CVP) were measured three times a day to control the intra-abdominal pressure (Table 1). The second day after the operation, the vital signs (PR=110-120/min) and patients' general condition improved. Bladder pressure was 18-20 mmHg and subsequently decreased to 8 mmHg three days later (normal range is 0-15 mmHg). The second laparotomy was considered to close abdominal fascia which was left untreated in the first surgery due to the patient's conditions. Moreover, reactive fluid was removed, and intestinal adhesion was released during the procedure; therefore, the abdominal wall was closed after the irrigation. The next day, tachycardia was improved and HR decreased to 70-80 bpm, and distension gradually decreased. She also had defecation and gas passing. The patient was discharged a few days later with a good general condition. The pathological report of uterus revealed severe congestion, focal haemorrhage, and coagulation necrosis. It confirmed the uterus atony (Figure 4).

This information is reported with the patient's informed consent.

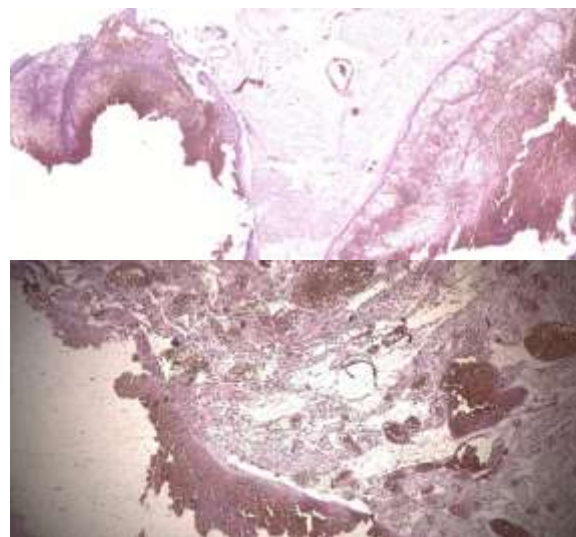


Figure 4. Microscopic images displaying hemorrhage, focal coagulation necrosis and dilated

Table 1. Patient's progress after decompressive laparotomy

	20 th Oct.	21 st Oct.	22 nd Oct.	25 th Oct.	28 th Oct.	30 th Oct.
WBC ,0 ³ /μl	18.5	17.3	16.8	13.3	15.1	25.2
Hb, g/dl	7.3	9.5	8.4	9.4	9.5	8.5
Hct, %	23.2	29.1	10.5	28.4	29	28.4
Plt, 10 ³ /μl	162	395	270	639	580	540
ALT, IU/L	6		8			
AST, IU/L	10		10			
Bilirubin Total, mg/dl	0.6		0.7			
Cr, mg/dl	0.7	0.8	0.7	0.6	0.7	0.7
BUN, mg/dl	34					
Alb, g/L	2.6	2.7	2.8	2.9	2.4	2.8
PT, sec	16.7		13.6	15.2		
PTT, sec	35		26	34		
INR	1.64		1.15	1.39		
Bladder Pressure, mmHg	19		8			

WBC: White Blood Cell, Hb: Haemoglobin, Hct: Haematocrit, Plt: Platelet; ALT: Alanine transaminase, AST: Aspartate Aminotransferase, Bil T: Bilirubin total, Cr: creatinine, BUN: Blood urea nitrogen, Alb: Albumin, PT: Prothrombin Time, PPT: partial thromboplastin time, INR: international normalized ratio

Discussion

In this report, we presented the case of a woman who suffered from ACS following CS. The early detection and proper management saved the life of this patient. The onset of ACS requires prompt recognition and appropriately timed and staged intervention in order to optimize the outcome. ACS can be both primary and secondary. The causes of this disease include postoperative bleeding, mechanical intestinal obstruction, and postoperative closure of the abdomen under tension, ascites, and ileus (8). Intraoperative haemorrhage was the risk factor in our patient. IAP is routinely measured by bladder pressure. This pressure was measured at 18-20 mmHg in our patient; therefore, she was placed in the second grade of IAP, according to the World Society of the Abdominal Compartment Syndrome (9). Due to intra-abdominal pressure, perfusion of other internal organs is impaired and leads to an emergency condition. Decompression techniques should be performed if the pressure was above 15 mmHg (10). Supportive therapies along with surgical techniques improved the condition of our patient. Partial bowel obstruction can occur after any surgery; consequently, passing gas, defecation, abdominal distension, nausea, and vomiting need to be controlled (11). Numerous medical therapies have been proposed for the

management of these patients. The definitive treatment of ACS is based on optimal timing and staging of abdominal decompression and depends on the early identification of at-risk patients. The early diagnosis of at-risk patients is mandatory for the successful management of ACS. The first step is acute resuscitation, hemodynamic stability, and change of body position. In addition, nasogastric/colonic decompression may be effective. Nevertheless, the administration of sedation, analgesia, and neuromuscular blockade strategies may alleviate the need for decompressive laparotomy (12-14). However, the role of albumin and diuretics has not been well-established. The final step in treatment is an emergency surgical or radiologic intervention. Percutaneous catheter drainage may be a beneficial approach. However, decompressive laparotomy as a definitive procedure in the treatment of ACS leads to the successful resolution of this disease (15). In our case, the first step was hydration and mechanical decompression techniques. Nonetheless, serum electrolyte balance and antibiotic therapy may solve the problem due to reduced edema and inflammation; consequently, surgical technique was required (16). In the surgical procedure, the manual evacuation of gastrointestinal tract contents was effective; subsequently, saline irrigation resolved the problem. In this

syndrome, fascia is not closed; therefore, the skin should be closed temporarily, and the repair would be completed in the second surgery (17).

Conclusion

ACS during cesarean section is a rare event which is associated with a high risk of mortality. This complication is accompanied by organ dysfunction; therefore, delayed diagnosis and treatment can cause irreversible damages. The physicians should assess all signs after CS delivery. In this regard, ACS should be suspected in the event of some complications after CS. They include massive abdominal distention, nausea, vomiting, pain, fever, difficulty breathing, the sign of hypovolemia, and decreased urine output. The identification of at-risk patients, early recognition, and appropriate management, and timed intervention contribute greatly to the effective management of this condition.

Acknowledgments

Thanks for the cooperation of the personnel of academic Hospital in Ghaem Mashhad.

Conflicts of Interest

The authors declare no conflicts of interest.

References

- Rogers WK, Garcia L. Intraabdominal hypertension, abdominal compartment syndrome, and the open abdomen. *Chest*. 2018; 153(1):238-250.
- Tyagi A, Singh S, Kumar M, Sethi AK. Intra-abdominal pressure and intra-abdominal hypertension in critically ill obstetric patients: a prospective cohort study. *International Journal of Obstetric Anesthesia*. 2017; 32:33-40.
- Seyhan TO, Orhan-Sungur M, Basaran B, Karadeniz MS, Demircan F, Xu Z, et al. The effect of intra-abdominal pressure on sensory block level of single-shot spinal anesthesia for cesarean section: an observational study. *International Journal of Obstetric Anesthesia*. 2015; 24(1):35-40.
- Handschin AE, Weber M, Renner E, Clavien PA. Abdominal compartment syndrome after liver transplantation. *Liver Transplantation*. 2005; 11(1):98-100.
- Milanchi S, Magner D, Lo SK, Klein AS, Colquhoun SD, Nissen NN. Abdominal compartment syndrome secondary to retroperitoneal hematoma as a complication of ERCP after liver transplantation. *Transplantation Proceedings*. 2007; 39(1):169-171.
- Leclerc B, Du Mont LS, Parmentier AL, Besch G, Rinckenbach S. Abdominal compartment syndrome and ruptured aortic aneurysm (SCA-AAR). *Medicine (Baltimore)*. 2018; 97(25):e11066.
- Hefler-Frischmuth K, Lafleur J, Brunnmayr-Petkin G, Roithmeier F, Unterrichter V, Hefler L, et al. Compartment syndrome after gynecologic laparoscopy: systematic review of the literature and establishment of normal values for postoperative serum creatine kinase and myoglobin levels. *Archives of Gynaecology and Obstetrics*. 2017; 296(2):285-293.
- Mohmand H, Goldfarb S. Renal dysfunction associated with intra-abdominal hypertension and the abdominal compartment syndrome. *Journal of the American Society of Nephrology*. 2011; 22(4):615-621.
- De Waele JJ, Ejiike JC, Leppäniemi A, De Keulenaer BL, Kirkpatrick AW, Roberts DJ, et al. Intra-abdominal hypertension and abdominal compartment syndrome in pancreatitis, paediatrics, and trauma. *Anaesthesiology Intensive Therapy*. 2015; 47(3):219-227.
- Lee RK. Intra-abdominal hypertension and abdominal compartment syndrome a comprehensive overview. *Critical Care Nurse*. 2012; 32(1):19-31.
- Shamimi K, Aminian A, Moazami F, Jalali M. Intra-abdominal hypertension and abdominal compartment syndrome in the surgical intensive care unit of Imam Khomeini Hospital: a 12 months study. *Tehran University Medical Journal TUMS Publications*. 2006; 64(12):76-83.
- Kaya B, Tuten A, Daglar K, Onkun M, Sucu S, Dogan A, et al. B-Lynch uterine compression sutures in the conservative surgical management of uterine atony. *Archives of Gynecology and Obstetrics*. 2015; 291(5):1005-1014.
- Kimmich N, Engel W, Kreft M, Zimmermann R. Uterus wrapping: a novel concept in the management of uterine atony during cesarean delivery. *Case Reports in Obstetrics and Gynecology*. 2015; 2015:195696.
- Loftus T, Moore F, VanZant E, Bala T, Brakenridge S, Croft C, et al. A protocol for the management of adhesive small bowel obstruction. *The Journal of Trauma and Acute Care Surgery*. 2015; 78(1):13.
- Chuong AM, Corno L, Beaussier H, Boulay-Coletta I, Millet I, Hodel J, et al. Assessment of bowel wall enhancement for the diagnosis of intestinal ischemia in patients with small bowel obstruction: value of adding unenhanced CT to

- contrast-enhanced CT. *Radiology*. 2016; 280(1):98-107.
16. Maluso P, Olson J, Sarani B. Abdominal compartment hypertension and abdominal compartment syndrome. *Principles of Adult Surgical Critical Care*. 2016; 32(2):233-240.
17. Reibetanz J, Germer CT. Das abdominelle Kompartmentsyndrom. *Medizinische Klinik-Intensivmedizin und Notfallmedizin*. 2013; 108(8):634-638.