

## Rectal Buttonhole Tear Following Operative Vaginal Delivery

Atiyeh Vatanchi (MD)<sup>1</sup>, Leila Pourali (MD)<sup>2\*</sup>, Asiyeh Maleki (MD)<sup>1</sup>, Maede Khosravi (MD)<sup>3</sup>, Shima Hatami (MD)<sup>3</sup>, Zahra Behnam (MD)<sup>3</sup>

<sup>1</sup> Assistant Professor, Department of Obstetrics and Gynecology, Faculty of Medicine, Mashhad University of Medical Sciences, Mashhad, Iran

<sup>2</sup> Associate Professor, Department of Obstetrics and Gynecology, Faculty of Medicine, Mashhad University of Medical Sciences, Mashhad, Iran

<sup>3</sup> Resident, Department of Obstetrics and Gynecology, Faculty of Medicine, Mashhad University of Medical Sciences, Mashhad, Iran

ARTICLE INFO	ABSTRACT
<p><b>Article type:</b> Case report</p>	<p><b>Background &amp; aim:</b> A rectal buttonhole tear during childbirth is an isolated laceration of rectal mucosa and vagina without involvement of anal sphincter that its management is challenging in obstetrics. The aim of this study was to report a case of rectal buttonhole tear following operative vaginal delivery.</p>
<p><b>Article History:</b> Received: 13-May-2022 Accepted: 26-Jun-2022</p>	<p><b>Case report:</b> A 31-year-old primigravid woman was admitted to the Maternity ward of a teaching hospital of Mashhad University of Medical Sciences for pregnancy termination. The patient underwent an induction of labor. She had a successful assisted vaginal delivery with vacuum. A Rectal buttonhole tear was found in in the rectovaginal septum, which was repaired immediately after delivery in operation room. Six weeks' follow-up visit showed a completely cured laceration and the patient reported no complaints of fecal incontinence or foul discharge.</p>
<p><b>Key words:</b> Digital Rectal Examinations Vacuum Extraction Delivery Obstetric Delivery Obstetric Labor Complication</p>	<p><b>Conclusion:</b> Rectal examination before and after suturing perineal tears following vacuum extraction can help the diagnosis of isolated laceration. Accurate evaluation and using the optimal surgical techniques are the main points to achieve the best results.</p>

► Please cite this paper as:

Vatanchi A, Pourali L, Maleki A, KhosraviM, Hatami Sh, Behnam Z. Rectal Buttonhole Tear Following Operative Vaginal Delivery. Journal of Midwifery and Reproductive Health. 2022; 10(3): 3405-3408. DOI: 10.22038/jmrh.2022.65536.1910

### Introduction

A buttonhole tear is a laceration of rectal mucosa and vagina which rarely occurs during delivery. It is usually an isolated incident and doesn't involve anal sphincter (1-3). However, it may be associated with sphincter injury in some cases. The overall incidence of OASI (obstetric anal sphincter injuries) in the UK is 2.9%, with a higher incidence in primiparity (6.1%) compared to multiparity (1.7%); although the exact incidence of rectal button hole tears is not known, these injuries are rare (4,5).

Searching literatures showed very limited studies and there was no comprehensive statistics on grade 3 and 4 obstetric injuries in Iran. In the study in Mashhad which examined 7 cases, four (57.2%) were multiparous and three cases were primiparous. The most risk factors associated with perineal lacerations included 6 cases of induction by oxytocin, 3 cases of

gestational diabetes, 3 cases of postdate pregnancy and 2 cases of macrosomia (6).

If a thorough rectal examination is performed, this damage will be identified immediately after delivery. Otherwise, it is diagnosed late with abnormal discharge and eventually rectovaginal fistula. Here, we reported a case of rectal buttonhole injury following vacuum delivery.

### Case report

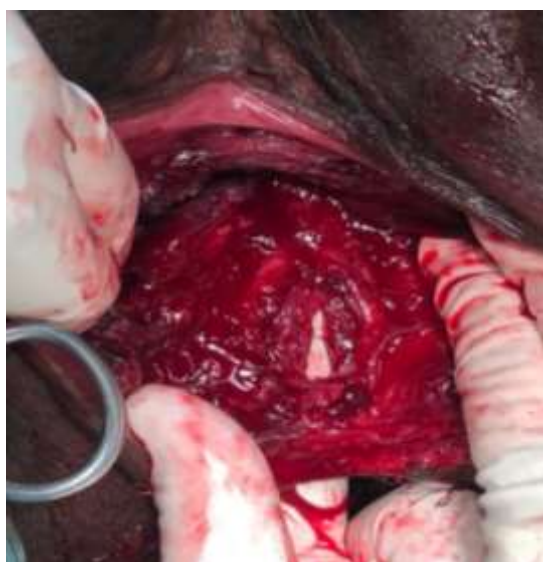
This A 31-year-old primigravid woman was admitted to the Maternity ward of a teaching hospital of Mashhad University of Medical Sciences, Mashhad, Iran, for pregnancy termination. The primary general consent form was completed by the patient at the time of admission. She had a history of non-severe gestational hypertension since 20<sup>th</sup> week. At

\* Corresponding author: Leila Pourali, Associate Professor, Department of Obstetrics and Gynecology, Faculty of Medicine, Mashhad University of Medical Sciences, Mashhad, Iran. Tel: 00985138012477; Email: pouralil@mums.ac.ir

admission, vital sign was stable and blood pressure was 140/90 mmHg. Laboratory evaluation showed normal values. Labor induction was started with low dose oxytocin regiment. First stage of labor progressed normally. With regard of labor arrest in the second stage of labor for 2 hours in occiput posterior position and non-reassuring fetal heart rate tracing, operative vaginal delivery was performed using the silastic cup at the fetal head station of +2 by an experienced professor. To rule out the included vaginal epithelium, cup was completely checked. A left mediolateral episiotomy was also done.

After just once trying, vaginal delivery occurred successfully and a female neonate (3350 gr) was born with Apgar score of 9 -10. The placenta and membranes were completely delivered.

Vaginal and rectal examinations were performed immediately after delivery. Rectovaginal examination revealed a 2 cm button-hole laceration in the rectovaginal septum, 5 cm above the anal canal and medial to the episiotomy incision with regular edges (Figure 1). The external sphincter appeared intact, but the internal sphincter was injured.



**Figure 1.** Postpartum rectal buttonhole tear

The patient was transferred to the operation room. The laceration was repaired under spinal anesthesia in dorsal lithotomy position. First, the rectal mucosa was sutured with continuous

Monocryl 2-0, the internal sphincter was repaired by continuous 2-0 vicryl suture, and then the rectovaginal septum and the vaginal mucosa were repaired by the same suture, respectively.

Prophylactic intravenous antibiotic (Cephazolin 2g) was given intraoperative and oral metronidazole continued for 5 days. Low residue regimen was started postoperatively and the analgesic medication added to oral antibiotics. She was discharged on the 3<sup>rd</sup> day after the assurance of normal defecation and normal vital sign. Magnesium hydroxide also was continuing as a stool softener. In the follow-up visit of 6 weeks, the patient had no complaint of perineal pain or anal incontinence, also the rectovaginal examination showed normal anal sphincter tonicity.

## Discussion

Perineal tears are divided into four degrees (sultan's classification) according to the extent of the injury (Table 1) (2,3,7).

**Table 1.** Sultan's classification of perineal trauma

Degree	Definition
<b>1st degree</b>	Laceration of vaginal epithelium or perineal skin only
<b>2nd degree</b>	Involvement of the perineal muscles but not the anal sphincter
<b>3rd degree</b>	Disruption of the anal sphincter muscles 3a: <50% thickness of external sphincter torn 3b: >50% thickness of external sphincter torn 3c: internal sphincter torn
<b>4th degree</b>	Third degree tear with disruption of the anal epithelium as well

Risk factors for OASIS include assisted vaginal delivery, birth weight > 4 kg, persistent occipitoposterior presentation, nulliparity, tissue factors, and second stage >1 hour (8). Operative vaginal delivery is an important risk factor for 3rd and/or 4th degree perineal tears. However, the risk is reduced by vacuum than that forceps (9). In the present case, nulliparity and vacuum assisted delivery were the main risk factors for buttonhole rectal laceration.

There is no separate classification for isolated obstetrical rectal tears (known as button hole)

without injury to the sphincter. There are few reports for this type of injury. It seems that the most important reason for the rarity of this complication is underdiagnoses and underreporting (10,11). OASIS and isolated rectal buttonhole tears should always be excluded after all vaginal deliveries regardless of perineal injury (3). The guideline published by the RCOG (2015) states that following vaginal delivery, anal sphincter injury and anorectal mucosal injury cannot be excluded without performing a rectal examination. The American College of Obstetricians and Gynecologists emphasized this guideline ([ACOG], 2018) (4,12).

In the present case, despite the normal weight of the neonate and performing episiotomy, this happened unexpectedly, which shows the importance of rectovaginal examination after delivery. Actually in the current case, the isolated rectal laceration was diagnosed only after precise digital rectal examination and was not observed at the first visual inspection. NICE and RCOG both recommend to conduct a rectal examination before and after suturing perineal tears (RCOG, 2015; NICE, 2017). The rectal examination is performed before repair to classify the tear accurately and is performed after repair to check that the repair is complete and ensure that no sutures are penetrating the anorectal mucosa (4,13).

There are two types of missed tears; one where the tear is missed completely and recorded as a first or second degree tear, and the other where it is under-classified. Both of these can impact the clinical outcome and quality of life. The evidence showed that tears identified during delivery and repaired appropriately at the same time have improved patient's outcomes, including anal incontinence, perineal pain, dyspareunia and levatorani injuries, compared to when they are remaining undiagnosed (14,15).

In a review of literature, Roper and coworkers (11) reported case series of this type of injury. They reviewed nine published case reports (four instrumental deliveries (9,16,17), two vaginal breech and three normal vaginal deliveries). They also reported 3 cases of buttonhole tears following vaginal delivery from

April 2012 to January 2020 in their center. All three cases had an associated episiotomy. Of which, one was a vacuum delivery and two were forceps delivery. In all cases, post-operative antibiotics and laxatives were prescribed for a minimum of 3 days (11).

The type of the suture material, operator skills and the technique used for repair are the three main factors which influence the short and long term outcomes of perineal repair. In most institutions, chromic catgut has been largely replaced by synthetic, delayed-absorbable materials, such as polyglactin 910 and polyglycolic acid, as use of chromic catgut appears to be associated with more postpartum discomfort (18). The continuous technique is faster and uses the smallest amount of suture material (19). In the present case, 2-0 vicryl suture with continues technique repair was used and no wound dehiscence or infection occurred. Postoperative management including appropriate antibiotics, low residue regimen, analgesics, laxatives and precise perineal cleaning with water are the most important postoperative care after perineal repair (20).

We considered all the mentioned postoperative management for the present case, so prophylactic intravenous antibiotic (Cephazolin 2g) was given intraoperative and oral metronidazole continued for 5 days. Low residue regimen was started postoperatively and the analgesic medication and laxative were added to oral antibiotics. The common practice is to schedule women with OASIS repair for a 6 weeks postpartum follow-up visit (21). In the follow-up visit, the present patient had no perineal pain, discomfort or anal incontinence. The rectovaginal examination showed normal anal sphincter tonicity.

## Conclusion

Precise evaluation and using the optimal surgical technique are the main points to achieve the best consequences after obstetrics perineal lacerations repair.

## Acknowledgements

We appreciate the Maternity ward of the hospital to provide the resources needed for this report.

## Conflicts of interest

Authors declared no conflicts of interest.

## References

1. Thakar R, Sultan AH. Management of obstetric anal sphincter injury. *The Obstetrician & Gynaecologist*. 2003; 5(2): 72-78.
2. Sultan AH, Thakar R. Lower genital tract and anal sphincter trauma. *Best practice & research Clinical obstetrics & gynaecology*. 2002; 16(1): 99-115.
3. Sultan AH, Thakar R, Fenner DE, editors. *Perineal and anal sphincter trauma: diagnosis and clinical management*. Springer Science & Business Media. 2007.
4. Adams EJ, Fernando RJ. Management of third- and fourth-degree perineal tears following vaginal delivery. *Royal College of Obstetricians and Gynaecologists*. 2001.
5. Thiagamoorthy G, Johnson A, Thakar R, Sultan AH. National survey of perineal trauma and its subsequent management in the United Kingdom. *International urogynecology journal*. 2014; 25(12): 1621-1627.
6. Jahani Shourab N, Mirteimouri M, Latifnejad Roudsari R. A case series of severe perineal lacerations during normal childbirth. *The Iranian Journal of Obstetrics, Gynecology and Infertility*. 2018; 21(8): 103-114.
7. Simó González M, Porta Roda O, Perelló Capó J, Gich Saladich I, Calaf Alsina J. Mode of vaginal delivery: a modifiable intrapartum risk factor for obstetric anal sphincter injury. *Obstetrics and gynecology international*. 2015; 2015.
8. Simhan H, Krohn M, Heine RP. Obstetric rectal injury: risk factors and the role of physician experience. *The Journal of Maternal-Fetal & Neonatal Medicine*. 2004; 16(5): 271-274.
9. Shaaban KA. An isolated rectovaginal tear as a complication of vacuum delivery. *Journal of obstetrics and gynaecology: the journal of the Institute of Obstetrics and Gynaecology*. 2008; 28(1): 106.
10. Athanasiou S, Mousiolis A, Grigoriadis T, Antsaklis A. Postpartum traumatic rectal tear after normal vaginal delivery with an intact anal sphincter. *Journal of Gynecologic Surgery*. 2012; 28(2): 176-178.
11. Roper JC, Thakar R, Sultan AH. Isolated rectal buttonhole tears in obstetrics: case series and review of the literature. *International Urogynecology Journal*. 2020; 32(7): 1761-9.
12. Tsakiridis I, Mamopoulos A, Athanasiadis A, Dagklis T. Obstetric anal sphincter injuries at vaginal delivery: a review of recently published national guidelines. *Obstetrical & gynecological survey*. 2018; 73(12): 695-702.
13. Kenyon S, Ullman R, Mori R, Whittle M. Care of healthy women and their babies during childbirth: summary of NICE guidance. *BMJ*. 2007; 335(7621): 667-668.
14. Taithongchai A, Veiga SI, Sultan AH, Thakar R. The consequences of undiagnosed obstetric anal sphincter injuries (OASIS) following vaginal delivery. *International urogynecology journal*. 2020; 31(3): 635-641.
15. Volløyhaug I, Taithongchai A, Van Gruting I, Sultan A, Thakar R. Levator ani muscle morphology and function in women with obstetric anal sphincter injury. *Ultrasound in Obstetrics & Gynecology*. 2019; 53(3): 410-416.
16. Byrne H, Sleight S, Gordon A, Sella D, Abrahams Y. Unusual rectal trauma due to compound fetal presentation. *Journal of obstetrics and gynaecology: the journal of the Institute of Obstetrics and Gynaecology*. 2006; 26(2): 174-175.
17. Morrel B, Flu PK, Straub MJ, Vierhout ME. Isolated rectal lesions during parturition. *Acta obstetrica et gynecologica Scandinavica*. 1996; 75(5): 495-497.
18. American College of Obstetricians and Gynecologists. *ACOG Practice Bulletin No. 120: Use of prophylactic antibiotics in labor and delivery*. *Obstetrics and gynecology*. 2011; 117(6): 1472-1483.
19. Farrell SA, Flowerdew G, Gilmour D, Turnbull GK, Schmidt MH, Baskett TF, Fanning CA. Overlapping compared with end-to-end repair of complete third-degree or fourth-degree obstetric tears: three-year follow-up of a randomized controlled trial. *Obstetrics & Gynecology*. 2012; 120(4): 803-808.
20. Jones HW, Rock JA. *Te Linde's operative gynecology*. 12nd ed. Philadelphia; Wolters Kluwer; 2020.
21. Committee on Practice Bulletins-Obstetrics. *ACOG Practice Bulletin No. 198: Prevention and Management of Obstetric Lacerations at Vaginal Delivery*. *Obstetrics & Gynecology*. 2018; 132(3): e87-e102.