

Comparing Diagnostic Accuracy of Purple Line with Transverse Diagonal of Michaelis sacral to Predict Labor Progress in Nulliparous and Multiparous Women

Masoumeh Kordi (MSc)¹, Morvarid Irani (MSc)^{2*}, Fatemeh Tara (MD)³, Habibollah Esmaily (PhD)⁴

¹ Lecturer, Department of Midwifery, School of Nursing and Midwifery, Mashhad University of Medical Sciences, Mashhad, Iran

² Graduate, MSc in Midwifery, School of Nursing and Midwifery, Mashhad University of Medical Sciences, Mashhad, Iran

³ Associate Professor, Department of Obstetrics and Gynecology, School of Medicine, Mashhad University of Medical Sciences, Mashhad, Iran

⁴ Associate Professor, Department of Biostatistics and epidemiology, School of Health, Mashhad University of Medical Sciences, Mashhad, Iran

| ARTICLE INFO | ABSTRACT |
|--|---|
| <p><i>Article type:</i> Original article</p> <hr/> <p><i>Article History:</i> Received: 11-May-2013 Accepted: 26-Aug-2013</p> <hr/> <p><i>Key words:</i> Diagnostic test Labor Purple line Transverse Diagonal of the Michaelis Sacral</p> | <p>Background & aim: One of the key aspects of maternal care is observing labor progress. Careful assessment of labor progress could provide mothers to be referred on time and could minimize the maternal and neonatal morbidity. This study aimed to compare diagnostic accuracy of purple line with transverse diagonal of Michaelis sacral rhomboid to predict labor progress in nulliparous and multiparous women who referred to Om-ol-banin Hospital, Mashhad, Iran from April to August 2012.</p> <p>Methods: In this double-blind diagnostic accuracy study, 350 nulliparous and multiparous women with a single pregnancy in vertex presentation and gestational age of 38-42 week who admitted in state hospitals of Mashhad were selected using convenience sampling. The transverse diagonal of the Michaelis sacral rhomboid area was measured in cervical dilatation of ≤ 3 centimeters. Also labor progress and presence or absence of purple lines between the buttocks in the lateral position in the active phase of labor was controlled hourly. Data were analyzed by SPSS version 16 using Mann-Whitney U and Chi-square test.</p> <p>Results: The mean age of the women was 25.22 ± 5 years. Out of 350 women enrolled, 61.2% were primigravidas and 38.8% were multigravidas. Presence of the purple line with 68.57% sensitivity, 42.66% specificity, and 80.57% validity was accompanied with normal labor progress. Also transverse diagonal of the Michaelis sacral cut-off point of ≥ 98.5 millimeter was accompanied with normal labor progress with 86.5% sensitivity, 59.45% specificity and 79.65% validity.</p> <p>Conclusion: Transverse diagonal of the Michaelis sacral is better predictor for observing labor progress in comparison with purple line.</p> |

► Please cite this paper as:

Kordi M, Irani M, Tara F, Esmaily HA. Comparing Diagnostic Accuracy of purple line with Transverse Diagonal of Michaelis sacral to Predict labor Progress in Nulliparous and multiparous Women. Journal of Midwifery and Reproductive Health. 2013; 1(1):7-12.

Introduction

One of the key aspects of maternal care is observing labor progress, as the lack of labor progress is one of the two main causes of cesarean which could increase abnormal labor progress, maternal death, perinatal death and labor injuries. If labor abnormalities are not diagnosed and managed on time, it will cause the death of mother, uterine rupture, postpartum hemorrhage, postpartum infections,

genital system fistulas, and adverse fetal outcomes such as birth asphyxia, septicemia, nervous trauma, and death.

A total of 600,000 women die because of pregnancy and labor disorders annually across the world of which 95% occur in the developing countries and the most prevalent (30%) cause of such deaths are cephalopelvic disproportion (CPD) and abnormal labor progress (1,2). Most

* Corresponding author: Morvarid Irani, Graduate. Master of Midwifery, School of Nursing and Midwifery, Mashhad University of Medical Sciences, Mashhad, Iran. Tel: +98 9355319944 ; E-mail: Irani.morvarid@gmail.com

of these complications could be prevented by identifying women with abnormal labor progress and implementing on time interventions (3).

One of the predicting tools for labor progress is transverse diagonal of Michaelis sacral measurement (4). Recently, several studies have shown that the appearance of the purple line between the buttocks can also be used as a tool to predict the labor progress (5-7). Michaelis sacral region is a diamond-form area in sacral bone and its superior angle is between L₅-S₁, inferior angle at caudal part and lateral angle at superior- posterior spines (8). For the first time, Adolf Gusta Michaelis (1851) mentioned its importance for pelvic capacity (9, 10). The transverse diameter is visible between posterior-superior spines on the skin. Its measurement could be related to pelvic capacity (10) (Figure 1).

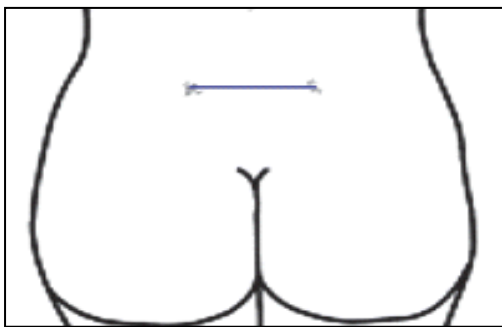


Figure 1. Transvers Diagonal of Michaelis Sacral

Rozenholc *et al.* (2007) showed that based on measuring transverse diagonal of Michaelis sacral could identify more than 50% of abnormal labor progresses. Liselele *et al.* (2000) and Alijahan *et al.* (2012) showed that transverse diagonal of Michaelis sacral has high diagnostic accuracy to assess labor progress (9-12).

Hobbs (1998) was the first one who mentioned that purple line is appeared as a purple point around anus during labor and progresses as cervical dilation increased. Direction of this progress is upward from intergluteal line to sacro-coccygeal joint like a thermometer in which mercury column moves upward (5) (Figure 2).

Researchers suggested that this congestion possibly occurs because of intra pelvic pressure

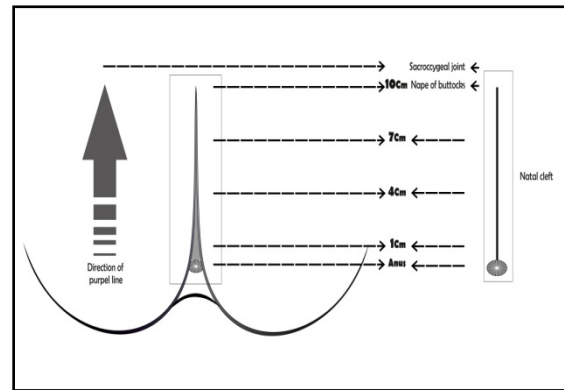


Figure 2. Direction of purple line

as the fetal head descends, which may account for the correlation between station of the fetal head and purple line length. The rhombus of Michaelis is a kite shaped area over the lower back that includes the lower lumbar vertebrae and sacrum. It is believed that this area of bone moves backwards during advanced labor, pushing out the wings of the ilea and increases the pelvic diameter (5). Shepherd *et al.* (2010) noted that the purple line is seen in 76% of the occasions. There was a significant correlation between the length of the purple line and cervical dilatation and the station of the fetal head.

By determining the diagnostic accuracy of labor progress tools and comparing them, we can determine clinical advantages of these tools and reduce the rate of maternal and neonatal complications.

To our knowledge, no study has been compared the diagnostic accuracy of purple line and transverse diagonal of Michaelis sacral to predict labor progress. Therefore, the aim of our study was to compare the diagnostic accuracy of purple line and transverse diagonal of Michaelis sacral rhomboid to predict labor progress in the nulliparous and multiparous women referred to Om-ol-banin Hospital of Mashhad between April and August 2012.

Materials and Methods

In this double-blind diagnostic accuracy study, 350 nulliparous and multiparous women who enrolled in the maternity ward of Om-ol-banin Hospital, Mashhad was studied. They enrolled in the study from April to August 2012. They were selected using convenience sampling.

The sample size was calculated after doing pilot study on 50 cases with 99% confidence intervals. The study plan was approved by the Research Ethics Committee (REC) of Mashhad University of Medical Sciences, Mashhad, Iran.

Women who had hip fractures, asymmetrical pelvis, lameness, apparent narrow pelvis, severe anxiety, BMI >30, or women who were younger than 18 or older than 35 and had cesarean due to other reasons except dystocia were excluded from the study. The women who had single pregnancy in vertex presentation, gestational age of 38-42 weeks without medical disorder included in the study.

In cervical dilation of ≤ 3 cm, transverse diagonal of Michaelis sacral (two horizontal notches visible on skin surface) was measured by a trained midwife in the standing position by a disposable tape. Then, the researcher observed the presence or absence of purple line between the buttocks in the lateral position every hour in the active phase of labor. The labor progress was controlled as well. Abnormal progress of labor was defined as cervical dilatation of less than 1 centimeter/ hour in the active phase for 2 hours or the fetal head descend less than 1 centimeter/ hour in both nulliparous and multiparous women, and also the duration of second stage more than 2 hours for nulliparous and 1 hour for multiparous women.

Instruments used in this study included self-structured questionnaires for data related to demographics, pregnancy, labor progress, delivery and newborn and also Spielberger Trait Anxiety Inventory. Tape was used for measuring transverse diagonal of Michael sacral and chronometer for determining duration of uterine contractions.

The validity of self-structured questionnaires was determined by content validity. The researcher's skill for measuring purple line and

transverse Diagonal of Michaelis sacral was confirmed by five training sessions at the presence of the supervisor and consultant.

Reliability of the fetus and labor progress questionnaire was determined by inter-rater reliability ($\alpha= 83.0$, $r=97.62$). Reliability of the researcher's skill for measuring purple line and transverse diagonal of Michaelis sacral was determined by inter-rater reliability ($\alpha= 0.92$, $r=84$).

After delivery, the subjects were divided into normal and abnormal labor progress, and diagnostic accuracy was calculated based on the presence or absence of purple line and the cut-off point of transverse diagonal of Michael sacral.

Data were analyzed by SPSS version16 using Mann-Whitney U and Chi-square test. Sensitivity, specificity, positive and negative indicative values were also calculated.

Results

Three hundred and seventy seven women were enrolled to participate, of which, 27 were excluded: Decelerations (n=18), cesarean section for severe bleeding (n=4), and withdraw from the study (n=5). Finally, the data 350 women were analyzed. The mean age of the women in this study was 25.22 ± 5 years. The mean gestation at birth was 39.8 ± 1.2 weeks, and the mean birth weight was 3332 ± 1543 grams out. Of the 350 women who enrolled, there were 61/2% primigravidas and 38.8% multigravidas. The baseline characteristics have been shown in Table 1.

In our study, out of 350 women, 275 (78.6%) had normal labor progress and (21.4%) experienced abnormal labor progress. The total number of vaginal exam was 1581 occasions. The line was appeared present during labor for 75.3% of the cases. The percentage of examinations where a purple line was present

Table 1. Baseline characteristics of subjects

| Variable | N | (%) |
|---------------------------|-----|--------|
| Primiparous women | 222 | (63.4) |
| Multiparous women | 128 | (36.6) |
| Spontaneous labor | 305 | (87.1) |
| Labor augmentation | 45 | (22.9) |
| Vaginal Delivery | 329 | (94) |
| Use of forceps and vacuum | 5 | (1.4) |
| Cesarean .Section | 16 | (4.6) |

Table 2. Diagnostic values of purple line in predicting labor progress

| Variable | Sensitivity | Specificity | Positive indicative value | Negative indicative value | Accuracy | Positive likelihood ratio |
|------------------------------------|-------------|-------------|---------------------------|---------------------------|----------|---------------------------|
| Presence or absence of purple line | 68.75% | 42.66% | 85.32% | 43.85% | 80.57% | 1.9 |

Table 3. Labor progress based on the cut-off point of transverse diagonal of Michaelis sacral

| Cut off point of transverse diagonal of Michaelis sacral | labor progress | | | | | | Chi-square test |
|--|----------------|---------|----------|---------|-------|---------|-------------------|
| | Normal | | Abnormal | | Total | | |
| | N | (%) | N | (%) | N | (%) | |
| ≥ 98.5 | 244 | (89.1) | 44 | (59.5) | 288 | (83.75) | df=1 P< 0.001* |
| < 98.5 | 30 | (10.9) | 30 | (40.5) | 60 | (17.25) | |
| total | 274 | (100.0) | 74 | (100.0) | 348 | (100.0) | |

Table 4. Diagnostic values of transverse diagonal of Michaelis sacral in predicting labor progress

| Variable | Sensitivity | Specificity | Positive indicative value | Negative Indicative value | Accuracy | Positive likelihood ratio |
|---|-------------|-------------|---------------------------|---------------------------|----------|---------------------------|
| Transverse diagonal of Michaelis sacral (≥98mm) | 89.05% | 59.45% | 84.72% | 50.0% | 79.65% | 2.1 |

In our study, out of 350 women, 275 (78.6%) had normal labor progress and (21.4%) experienced abnormal labor progress. The total number of vaginal exam was 1581 occasions. The line was appeared present during labor for 75.3% of the cases. The percentage of examinations where a purple line was present increased with an increase in cervical dilatation. So, the percentage increased from 66.4% in a cervical dilatation of 3 cm to 84% when cervical dilatation was 10 cm. The appearance of the purple line in the prediction of labor progress had 68.57% sensitivity, 42.66% specificity and 80.57% accuracy (Table 2).

Incision spot of the transverse diagonal of Michaelis sacral was determined based on the best sensitivity and specificity gained from Receiver Operating Characteristic (ROC) curve which was ≥ 98.5 millimeter. According to this incision spot, there were 83.75% normal labor progress and 17.25% abnormal labor progress (Table 3).

The transverse diagonal of the Michaelis sacral rhomboid area was ≥98.5 millimeter in the prediction of labor Progress. It had a sensitivity of 86.5%, a specificity of 59.45%, and an accuracy of 79.65% (Table 4).

Discussion

In this study, out of 350 women, 78.6% had normal labor progress (n=275) and 21.4% had abnormal labor progress (n=75). Alijahan *et al.* (2011) reported 87.5% normal labor and 17.25% abnormal labor progress. This difference was probably due to different definitions of labor progress. In addition, in their study only primiparous women were enrolled, whereas in this study, both primiparous and multiparous women were enrolled (4).

In our study, the percentage of appeared purple line and the mean transverse diagonal of Michaelis sacral was higher in women with normal labor progress. The appeared purple line in the prediction of labor progress had a sensitivity of 68.57%, a specificity of 42.66%, and an accuracy of 80.57%. The transverse diagonal of the Michaelis sacral rhomboid area was ≥ 98.5 millimeter in the prediction of labor progress and had a sensitivity of 86.5%, a specificity of 59/45%, and an accuracy of 79.65%. According to this study finding, transverse diagonal of the Michaelis sacral rhomboid area in comparison to purple line was the better predictor for the assessment of labor progress. Rozenholc *et al.* (2007) reported that

the highest sensitivity for transverse diagonal of Michaelis sacral based on incision spot was less than 9 cm (45.9%). The sensitivity calculated in this study was higher than the sensitivity calculated in their study. These differences was for the reason that they had different incision spots for transverse diagonal of Michaelis sacral, and in their study only primiparous women were enrolled, whereas in our study, primiparous and multiparous women were included. They also calculated the sensitivity for predicting abnormal labor progress, while we calculated the sensitivity for predicting normal labor progress (10). Kordi *et al.* (2011) reported that the sensitivity calculated for transverse diagonal of Michaelis sacral based on an incision spot of 9.6 cm was 60.7%, the specificity was 84.1%, and the accuracy was 81.2%. These differences could be because they had different definitions of labor progress. They also calculated the sensitivity for predicting abnormal labor progress, while we calculated the sensitivity for predicting normal labor progress (13).

The purple line appeared in 75/3% of the women during the active phase of labor. Bryne and Edmonds (1990) found that purple line appeared in 89% of the women (14). These differences may be due to having a different sample size and methods. They conducted a small study with 48 women in spontaneous labor, but we conducted a study with 350 women in spontaneous and induced labor. In their study, all the line observations and vaginal examinations were made by the same midwife, but in our study, all examinations of the line were checked by two midwives, which increase the accuracy of findings.

Women in their study were examined by different midwives, which reduce the accuracy of vaginal examination. Some studies reported accuracy for determining the exact cervical diameter of between 48.6% and 56.3%. Variation in vaginal examination up to 1 cm has been reported in 47% and up to 2cm in 25% by Koss and Bergsjö (15).

Buchmann *et al.* (2007) reported a difference in dilatation measurements by 2 cm or more in 11% of cases (16). Therefore, researchers have suggested that vaginal examination and care be carried out by one midwife (16,17).

Shepherd *et al.* (2010) found that the purple line appears in 76% of the women and the results of our study are in agreement with their findings (6). There was a significant association between white and non-white women, meaning that there was a purple line in 67.5% of the whites and 48.5% in the non-white women (7). In our study, the appearance for the purple line was higher than that in the aforementioned studies, which would be due to different sample size or different race and color. The appearance for the purple line in non-white women was less than white women.

One of the limitations of this study was the measurement of cervical dilatation and descending of the fetal head, subjectively, as there was no objective equipment to measure. Also, vaginal examination was considered as the gold standard; however, to improve the accuracy, we used only one midwife to perform the examination in all cases in order to minimize the confounding factors. The intensity of uterine contractions was determined by palpation and there was no possibility of internal monitoring.

Conclusion

Transverse diagonal of the Michaelis sacral is better predictor for monitoring labor progress in comparison with purple line. Thus, assessment of transverse diagonal of the Michaelis sacral could predict the abnormalities of labor progress which in turns causes on-time and appropriate management of mothers and as a consequence minimizes the maternal and neonatal morbidities.

Acknowledgements

This study is part of a Master dissertation approved by Mashhad University of Medical Sciences on April 2012, with approval Code of 900759. The financial support provided by Research Deputy is highly appreciated.

Conflict of Interest

The authors declare no conflicts of interest.

References

1. Cunningham F, Leveno K, Bloom S, Hauth J, Rouse D, Spong C. Williams Obstetrics. 23rd Edition. New York: The Mc Graw Hill Medical publishing; 2010.

2. Midwives TRCo. Evidence Based Guidelines for Midwifery-Led Care in Labor-Assessing Progress in Labor Practice Points. 2012.
3. Dixon L, Foureux M. The vaginal examination during labor: Is it of benefit or harm? New Zealand College of Midwives Journal 2010; 42:21-26.
4. Kordi M, Alijahan R. The Diagnostic Accuracy of External Pelvimetry to Predict Dystocia in Nulliparous Women. Zahedan Journal of Research in Medical Sciences 2012; 14(6):36-38.
5. Hobbs L. Assessing cervical dilatation without VEs. The Practising Midwife 1998; 1(11):34-35.
6. Shepherd A, Cheyne H, Kennedy S, McIntosh C, Styles M, Niven C. The purple line as a measure of labor progress: a longitudinal study. BioMed Central BMC Pregnancy and Childbirth 2010; 10(1):54.
7. Narchi NZ, Camargo J da CS de, Salim NR, Menezes M de O, Bertolino MM. The use of the "purple line" as an auxiliary clinical method for evaluating the active phase of delivery. Rev Bras Saúde Matern Infant 2011; 11(3):313-322.
8. Hamm B, Forstner R, Beinder E. MRI and CT Of the female pelvis. 1st ed. london: Springer publisher; 2007.
9. Liselele H, Boulvain M, Tshibangu K, Meuris S. Maternal Height and External Pelvimetry to Predict Cephalopelvic Disproportion in Nulliparous African Women: a Cohort Study. British Journal of Obstetrics and Gynaecology 2000; 107(1):947-952.
10. Rozenholc A, Ako S, Leke R, Boulvain M. The Diagnostic Accuracy of External Pelvimetry and Maternal Height to Predict Dystocia in Nulliparous Women: A Study in Cameroon. British Journal of Obstetrics and Gynaecology 2007; 114(1):630-635.
11. Alijahan R, Kordi M, Porjavad M, Ebrahimzadeh S, Mahmoudian A. The Diagnostic Accuracy of Clinical and External Pelvimetry in Prediction of Dystocia in Nulliparous Women. Journal of Shahid Sadoughi University of Medical Sciences 2011; 19(3):398-407.
12. Alijahan R, Kordi M, Pourjavad P, Ebrahimzadeh S. The Diagnostic Accuracy Of Clinical Pelvimetry In Nulliparous Women. The Iranian Journal of Obstetrics, Gynecology and Infertility 2011; 14(6):29-30.
13. Kordi M, Alijahan R, Pourjavad P, Ebrahimzadeh S, Mahmoudian A. The Diagnostic Accuracy of the Combination of Maternal Height and Transvers Diagonal of Michaelis sacral Rhomboid Area to Predict Dystocia in Nulliparous Women. Journal of Birjand University of Medical Sciences 2011; 17(3):174-182.
14. Bryne D, Edmonds D. Clinical method for evaluating progress in first stage of labor. The Lancet 1990; 335: 122.
15. Bergsjö P, Koss KS. Interindividual variation in vaginal examination finding during labor. Acta Obstetrics Gynecol Scand. 1982; 61(6):509-510.
16. Buchmann EJ, Libhaber E. Accuracy of cervical assessment in the active phase of labor. British Journal of Obstetrics and Gynaecology 2007; 114(7):833.
17. Tuffnell DJ, Bryce F, Johnson N, RJ. L. Simulation of cervical changes in labor: reproducibility of expert assessment. The Lancet 1989 4; 2 (8671):1089-90.