

Decreased Visual Acuity as the First Alarm Sign of Severe Preeclampsia: A Case Report

Atiyeh Vatanchi (MSc)^{1,2*}, Leila Pourali (MSc)^{2,3}, Ghodsieh Zamani (MSc)⁴, Maral Rezaei (MSc)⁵

¹ Assistant Professor, Department of Obstetrics and Gynecology, Faculty of Medicine, Mashhad University of Medical Sciences, Mashhad, Iran

² Supporting the Family and the Youth of Population Research Center, Mashhad University of Medical Sciences, Mashhad, Iran

³ Associate Professor, Department of Obstetrics and Gynecology, Faculty of Medicine, Mashhad University of Medical Sciences, Mashhad, Iran

⁴ Assistant Professor, Department of Ophthalmology, Faculty of Medicine, Mashhad University of Medical Sciences, Mashhad, Iran

⁵ Gynecologist, Department of Obstetrics and Gynecology, Faculty of Medicine, Mashhad University of Medical Sciences, Mashhad, Iran

ARTICLE INFO	ABSTRACT
Article type: Case report	Background & aim: Retinal detachment is an unusual complication of hypertensive disorder during pregnancy and its prevalence is 1% to 2% in women with severe preeclampsia and 10% in those with eclampsia. Here, we introduce a case of preeclampsia with first presentation of retinal detachment.
Article History: Received: 07-Jul-2023 Accepted: 27-Jan-2024	Case report: A 19-year-old primigravid woman at 32th weeks complained of suddenly decreased vision in both eyes. Ophthalmic examination revealed visual acuity of 2/10 in the right eye and 3/10 in the left one, suggesting central serousretinal detachment due to hypertensive retinopathy. Diagnosis of severe preeclampsia was confirmed considering to elevated blood pressure, proteinuria and retinal detachment. After 5 days, her vision started to improve and funduscopy showed resolving retinal detachment. At 40 days post-partum, her vision improved to 10/10 in both eyes.
Key words: Hypertensive Retinopathy Pregnancy Preeclampsia Retinal Detachment	Conclusion: This case report highlights the importance of complaint of blurred vision in pregnancy that could be the first alarm sign of severe preeclampsia.

► Please cite this paper as:

Vatanchi A, Pourali L, Zamani Gh, Rezaei M. Decreased Visual Acuity as the First Alarm Sign of Severe Preeclampsia: A Case Report. Journal of Midwifery and Reproductive Health. 2025; 13(2): 1-4. DOI: 10.22038/JMRH.2024.73528.2145

Introduction

Hypertensive disorders of pregnancy complicate up to 10% of pregnancies and are considered a significant cause of maternal and perinatal morbidity and mortality (1-2). Visual system may be affected in 30% to 100% of patients with (pre)eclampsia (3). Established ophthalmic entities associated with (pre)eclampsia are cortical blindness, serous retinal detachment, Purtscher-like retinopathy, central retinal vein occlusions, and retinal or vitreous hemorrhages. Ensuing visual symptoms include blurred vision, diplopia, amaurosis

fugax, photopsia, and scotomata, including homonymous hemianopsia. Visual disturbance is the most common visual complaint and the most common abnormality seen in the fundus is narrowing of retinal arterioles (4).

Since therapists are not familiar with the various manifestations of vision disorders associated with preeclampsia, and therefore the diagnosis of the underlying disease may be delayed, reports of these patients can help physicians become more familiar with this condition. Therefore, we report a case of

* *Corresponding author*; Atiyeh Vatanchi, Assistant Professor, Department of Obstetrics and Gynecology, Faculty of Medicine, Mashhad University of Medical Sciences, Mashhad, Iran. Tel: 05138012477; Email: vatanchia@mums.ac.ir



Copyright © 2023 Mashhad University of Medical Sciences. This work is licensed under a Creative Commons Attribution Noncommercial 4.0 International License <mailto:https://creativecommons.org/licenses/by/3.0/>

preeclampsia with first presentation of retinal detachment.

Case presentation

A 19-year-old primigravid woman at 32th weeks of gestation presented to the ophthalmology clinic of Khatam-Al-Anbia Eye Hospital in April 2019. She reported decreased visual acuity. The patient had no complications during pregnancy, but complained of sudden blurred vision in her left eye for one week and in her right eye for three days prior to the visit. On examination, the best corrected visual acuity (BCVA) was 1/10 in the right eye and 2/10 in the left eye. Fundus examination revealed bilateral serous retinal detachment in the macular area, confirmed by optical coherence tomography. No associated retinal hemorrhages, exudates, cotton-wool spots, disc edema, vitritis, or choroiditis lesions were observed.

A diagnosis of severe preeclampsia was confirmed due to the elevated blood pressure, proteinuria, and the presence of retinal

detachment. There was criteria for severe preeclampsia, including systolic blood pressure >160 and vision impairment. Consequently, magnesium sulfate for maternal and fetal neuroprotection and betamethasone for fetal lung maturation were administered. Despite neuroimaging (MRI and MRV) showing no abnormalities, the severity of preeclampsia and retinal detachment led to pregnancy termination via cesarean section. A preterm neonate with Apgar score of 8-10 and a weight of 1705 grams was delivered.

Post-surgery, the patient was initiated on losartan (25 milligrams twice daily) due to blood pressure readings of 140-150/100-110 mmHg. Echocardiography results indicated an ejection fraction of 55%, mild tricuspid regurgitation, and trace mitral regurgitation. Ophthalmology consultation reported 2/10 visual acuity in the right eye and 3/10 in the left eye, suggesting hypertensive retinopathy (Figure 1).

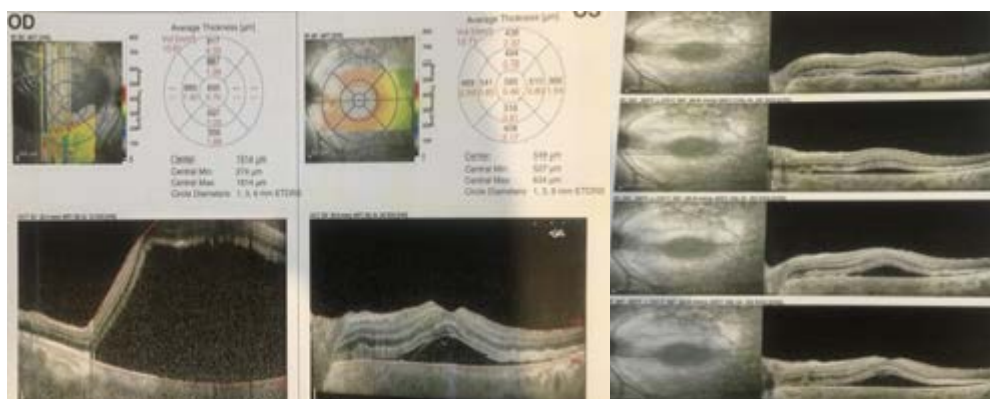


Figure 1. optical coherence tomography: "Elevation of Sensory retinae in both macula due to accumulation of hyporeflective fluid in subretinal space" Average central macular thickness is more in right eye

Five days after delivery, the patient's vision started to improve, and funduscopy revealed resolving retinal detachment. Forty days postpartum, her vision improved to 10/10 in both eyes, and her blood pressure was within the normal range. Informed consent for publication of the results was obtained from the patient.

Discussion

Hypertensive choroidopathy clinically presents with serous retinal detachments (SRDs) and yellowish retinal pigment epithelium (RPE) lesions and can complicate preeclampsia or eclampsia. Serous retinal detachments are typically bilateral and bullous and cause marked visual loss, but these changes usually resolve postpartum with the recovery of normal vision. However, severe cases can result in geographic chorioretinal atrophy, which occurs in up to 8.5% of preeclampsia patients (5). The exact pathophysiology of SRD is unknown.

However, it is believed to be caused by choroidal ischemia due to arteriolar vasospasm. This vascular insufficiency results in damage to the retinal pigment epithelium, transudation of fluid, and focal retinal detachment. Significant retinal vascular anomalies and retinal tears are generally not associated with this condition (6).

Retinal detachment is a rare complication of hypertensive disorder during pregnancy that has been reported in 1% to 2% of patients with severe preeclampsia and in 10% of patients with eclampsia (5). Choroidopathy may be the cause of retinal detachment. Most patients with retinal detachment in preeclampsia did not have any sequel. Medical treatment with antihypertensive drugs may be helpful in this condition (7). An Iranian study on 213 patients with hypertension pointed out that the chances of retinopathy increase with duration of hypertension. Therefore, early diagnosis and control of hypertension can reduce the rates of retinopathy considerably (8).

Hussain et al. reported a 24-year-old primigravid woman with diagnosis of preeclampsia serous retinal detachment at 30 weeks of gestation and in the absence of hypertension after a few days of headache. They concluded that even in the absence of hypertension providers should exercise vigilance for preeclampsia in women presenting with new-onset visual symptoms (9).

According to literature review, most of the patients' visual symptoms are manifested after diagnosis of preeclampsia (10). So visual loss without any other symptoms of preeclampsia is the interesting point of this case. Moreover, decreased vision as the first sign of severe preeclampsia initially draws the patient to an ophthalmologist and if the doctor did not doubt the correlation between this clinical finding and probability of preeclampsia there would be serious ocular and systemic complications. Signs of acute hypertensive retinopathy on fundus examination should prompt immediate referral for evaluation and treatment of the pregnancy-induced hypertension syndromes, preeclampsia and eclampsia. Termination of pregnancy may be the only efficient treatment to preserve patients' visual prognosis.

Conclusion

This case report highlights the importance of complaint of blurred vision in pregnancy that could be the first alarm sign of severe preeclampsia. Therefore, all patients with vision loss should be referred to a gynecologist as soon as possible to check for preeclampsia.

Declarations

Acknowledgements

We extend our gratitude to the patient involved for her participation.

Conflicts of interest

The authors declared no conflicts of interest.

Ethical considerations

All personal identifiers were removed to ensure the patient's privacy and confidentiality.

Ethical approval

Informed consent was obtained from the patient, ensuring confidentiality and adherence to ethical guidelines.

Funding

None.

Authors' contribution

Atiyeh Vatanchi was primarily responsible for drafting the manuscript, including the synthesis of clinical details and conceptual framework. Leila Pourali involved in drafting manuscript and data collection. Ghodsieh Zamani and Maral Rezaei collected relevant clinical data. All authors critically reviewed the manuscript and approved the final version for publication.

References

1. Braunthal S, Brateanu A. Hypertension in pregnancy: Pathophysiology and treatment. *SAGE Open Medicine*. 2019. 7: 2050312119843700-2050312119843700.
2. Bateman BT, Shaw KM, Kuklina EV, Callaghan WM, Seely EW, Hernández-Díaz S. Hypertension in women of reproductive age in the United States: NHANES 1999-2008. *PLoS one*. 2012; 7(4): e36171.
3. Alsamaan S, Alkhathami A, Alromaih AI, Almalki A, Alsuhbani AS, Al Ghramah AA, et al. Bilateral Exudative Retinal Detachment in Preeclampsia: A Case Report and Literature Review. *Cureus*. 2024; 16(5): e60866.
4. Vigil-De Gracia P, Ortega-Paz L. Retinal detachment in association with pre-eclampsia,

- eclampsia, and HELLP syndrome. *International Journal of Gynecology & Obstetrics*. 2011; 114(3): 223-225.
5. Raposo JTBV, Melo BCDS, Maciel NFBB, Leite SD, Rebelo ÓRC, et al. Serous Retinal Detachment in Pre-eclampsia: Case Report and Literature Review. *Revista Brasileira de Ginecologia e Obstetrícia*. 2020; 42(11): 7723.
 6. Gupta B, Singh N, Kumar V, Rajaram S, Goel N. Bilateral exudative retinal detachment in a patient with early onset severe preeclampsia. *Pregnancy Hypertension*. 2014; 4(4): 253-254.
 7. Williams B, Poulter NR, Brown MJ, et al. British hypertension society guidelines for hypertension management 2004 (BHS-IV): summary. *BMJ*. 2004; 328(7440): 634-640
 8. Besharati MR, Rastegar A, Shoja MR, Maybodi ME. Prevalence of retinopathy in hypertensive patients. *Saudi Medical Journal*. 2006; 27(11): 1725-1728.
 9. Hussain SA, O'Shea BJ, Thagard AS. Preeclamptic serous retinal detachment without hypertension: A case report. *Case Reports in Women's Health*. 2019; 21: e00098.
 10. Zeeman GG. Neurologic complications of pre-eclampsia. *Semin Perinatol*. 2009; 33(3): 166-172.