

Evaluation of the Uterine Causes of Female Infertility by Ultrasound: A Literature Review

Shohreh Irani (PhD)^{1,2}, Firoozeh Ahmadi (MD)³, Maryam Javam (BSc)^{1*}

¹ BSc of Midwifery, Department of Reproductive Imaging, Reproductive Biomedicine Research Center, Royan Institute for Reproductive Biomedicine, Iranian Academic Center for Education, Culture, and Research, Tehran, Iran

² Assistant Professor, Department of Epidemiology and Reproductive Health, Reproductive Epidemiology Research Center, Royan Institute for Reproductive Biomedicine, Iranian Academic Center for Education, Culture, and Research, Tehran, Iran

³ Graduated, Department of Reproductive Imaging, Reproductive Biomedicine Research Center, Royan Institute for Reproductive Biomedicine, Iranian Academic Center for Education, Culture, and Research, Tehran, Iran

ARTICLE INFO

Article type:
Review article

Article History:
Received: 07-Nov-2015
Accepted: 31-Jan-2017

Key words:
Female infertility
Menstrual cycle
Ultrasound
Uterus

ABSTRACT

Background & aim: Various uterine disorders lead to infertility in women of reproductive ages. This study was performed to describe the common uterine causes of infertility and sonographic evaluation of these causes for midwives.

Methods: This literature review was conducted on the manuscripts published at such databases as Elsevier, PubMed, Google Scholar, and SID as well as the original text books between 1985 and 2015. The search was performed using the following keywords: infertility, uterus, ultrasound scan, transvaginal sonography, endometrial polyp, fibroma, leiomyoma, endometrial hyperplasia, intrauterine adhesion, Asherman's syndrome, uterine synechiae, adenomyosis, congenital uterine anomalies, and congenital uterine malformations.

Results: A total of approximately 180 publications were retrieved from the respective databases out of which 44 articles were more related to our topic and studied as suitable references. In addition, 11 published books on ultrasonography and infertility were evaluated to provide more precise knowledge on the mentioned areas. According to the literature, ultrasonography has a crucial role in the investigation and differentiation of uterine disorders in females with infertility. However, the diagnosis depends on the day of menstruation, clinical presentations, and the suspected uterine disorder. In this review, we provided the key notes about proper timing of the ultrasound examination.

Conclusion: Ultrasonography is the first step imaging tool in the investigation of female infertility, which provides information for the diagnosis of uterine disorders. However, the accurate diagnosis depends on the "time of evaluation". Therefore, every midwife needs to learn about the "optimum timing" for ultrasound evaluation based on each patient.

► Please cite this paper as:

Irani Sh, Ahmadi F, Javam M. Evaluation of the Uterine Causes of Female Infertility by Ultrasound: A Literature Review. Journal of Midwifery and Reproductive Health. 2017; 5 (2): 919-926. DOI: 10.22038/jmrh.2017.8252

Introduction

Infertility is a widespread phenomenon that affects approximately 10-15% of the couples around the world (1, 2). There are several congenital or acquired uterine disorders, which cause infertility in the females. The acquired uterine abnormalities that are responsible for female infertility include polyps, some types of fibromas, adenomyosis, and some endometrial disorders such as intrauterine adhesions. On the other hand, the congenital uterine anomalies

account for about 3% of the infertile women and is categorized in seven classes, which will be described in details later (1-5).

Sonography is known as the first imaging modality in the investigation of the female pelvis to detect the mentioned disorders among the infertile females. It is an "accurate, non-invasive, and cost-effective" modality, which provides useful knowledge for the detection and characterization of the possible female infertility

* Corresponding author: Maryam Javam, Graduated, Department of Reproductive Imaging, Reproductive Biomedicine Research Center, Royan Institute for Reproductive Biomedicine, Iranian Academic Center for Education, Culture, and Research, Tehran, Iran. Tel: 9774066673; Email: maryam_javam@yahoo.com

factors (1, 2, 4-6). All infertile women undergo an initial ultrasound pelvic exam (baseline sonography) to investigate the probable causes of infertility. A careful pelvic ultrasound, particularly transvaginal sonography (TVS), can detect the uterine abnormalities, ovarian disorders, and other pathologic conditions, which lead to female infertility (1,2,4-8). Therefore, it can help the midwives, physicians, gynecologists, and infertility experts to examine the infertile women and make better treatment choices for these patients.

Hackeloer examined the role of ultrasound in investigation and management of female infertility in a review article in 1984. He precisely described the uterine abnormalities, ovarian disorders, and adnexal masses, which cause infertility using ultrasound images (9). Recently, Hrehorcak and Nargund (2011) have published a review study on the new perspective of diagnosing female infertility by advanced ultrasound techniques (10). There are a number of reviews targeting this issue, however, all of them are written by radiologists and gynecologists and provide advanced and specific knowledge for the specialists.

To the best of our knowledge, no study has been published in this area for the midwives. Since many midwives work at the infertility treatment centers or personal offices, they interface with infertile females and need to involve in the infertility assessment. Ultrasound scan is one of the most used diagnostic tools for the infertility workup. Therefore, every midwife needs to learn about the application of the ultrasound and management of the patients based on abnormal findings. Nevertheless, there are not enough learning opportunities for midwives in this area. With this background in mind, the present study aimed to provide useful practical knowledge about the ultrasonography assessment of female infertility and give a good chance to midwives to further learn about this issue.

Materials and methods

This literature review was conducted on the articles investigating the diagnosis of uterine causes of infertility by means of ultrasound scan. The articles published in such databases as PubMed, Elsevier, Google Scholar, and SID, as well

as the original text books between 1985 and 2015 were employed. A careful search was performed using the following keywords: "infertility", "uterus", "ultrasound scan", "transvaginal sonography", "endometrial polyp", "fibroma", "leiomyoma", "endometrial hyperplasia", "intra-uterine adhesions", "Asherman's syndrome", "uterine synechiae", "adenomyosis", "congenital uterine anomalies", "congenital uterine malformations", and "timing+ultrasound scan".

The articles, which were written in English or Persian and contained helpful data on "diagnostic criteria of uterine disorders on transvaginal ultrasound scan" and "proper timing of the ultrasound examination" were considered as proper references. All manuscripts were carefully assessed, and the proper articles were selected to be studied. The irrelevant articles or those written in other languages were excluded from the study.

Finally, a total of approximately 180 manuscripts were carefully assessed. Out of these, 12 articles were not published in English or Persian, 16 manuscript provided diagnostic criteria for hysteroscopy instead of TVS, 30 articles provided diagnostic accuracy of TVS instead of diagnostic criteria, and 78 papers did not discuss about the timing of the ultrasound scan. Therefore, 136 manuscripts were not thoroughly related to the topic of interest and excluded from the study. The remained 44 articles met the inclusion criteria and were studied as suitable references. In addition, 11 books on ultrasonography and infertility were evaluated to provide more precise knowledge on the investigated areas (Figure 1).

Results

We gathered the useful findings of the reviewed studies on uterine causes of female infertility and the key points on the diagnosis of these causes by ultrasonography, which were as follows

Acquired abnormalities

Polyps

Endometrial polyps are benign localized overgrowth glands, blood vessels, and stroma within the uterine cavity (1, 3, 11, 12). They mostly originate from the fundal region and extend to the internal os and may be seen single

or multiple. Their size differs from a few millimeters to centimeters and may be sessile or pedunculated (1, 11). There are some risk factors recognized to cause polyps, including age, hypertension, obesity, and tamoxifen use; however, the definite cause of polyps is unknown. The symptoms do not depend on the size, number, or location of the polyps (11-15).

Polyps are most often asymptomatic;

nevertheless, they commonly cause abnormal vaginal bleeding and infertility (11, 12, 15). The management of the females with endometrial polyps depends on the symptoms, fertility issues, and risk of malignancy (1). Polypectomy by means of hysteroscopy is considered as an effective and safe gold standard for both diagnosis and treatment of this condition, especially in case of infertility treatment (11, 14, 16).

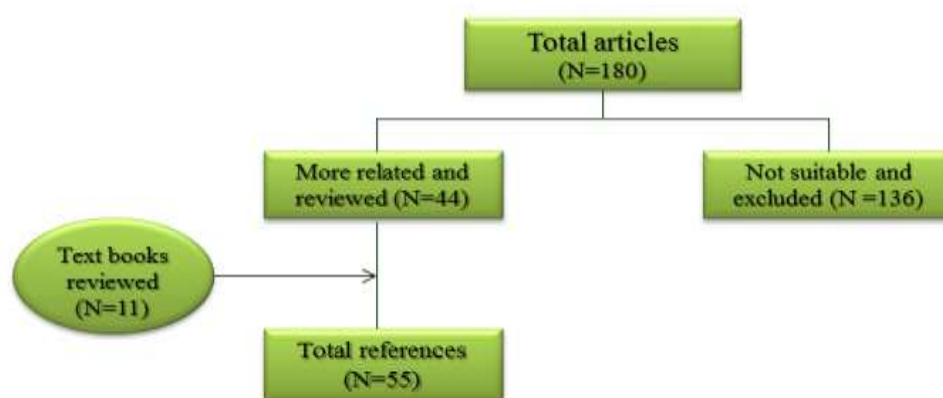


Figure 1. Study design

TVS is identified as the best diagnosis tool in this regard; however, it is better to be performed before day 10 of the cycle to decrease the risk of false-positive and false-negative findings (1). Regarding this, days 4-6 are preferred (17) since the endometrium has its thinnest thickness during this period (1, 11, 17). It is important to note that sonography needs to be performed by an experienced sonographer because differentiation of polyps from the clot, synechiae, submucosal fibroid, and hyperplasia must be considered for correct diagnosis (17).

Fibromas

Fibromas are benign tumors of the uterus, which mostly originate from smooth muscle. However, they may contain various amount of fibrous connective tissue (3, 18-21). They are the most common pelvic masses among the reproductive aged women, which is found in 20-40% of these population (18, 19). Although the exact cause of this condition is unknown, these tumors are hormone-related and respond to both estrogen and progesterone. However, several possible risk factors are raised, including

age, family history, ethnicity, weight, diet, smoking, pregnancy, and hormone replacement therapy (18-21).

Fibromas, which are also known as myomas, leiomyomas, and fibroids, arise within the uterine myometrium, nevertheless, they may be sometimes detected in the cervix, ovaries, or broad ligament. Fibromas are classified into three groups based on their location: (1, 3, 18-20, 22, 23).

1. Intramural fibroids are the most prevalent types, located within the myometrium and totally surrounded by it.
2. Subserosal fibroids are externally extending to the serosa, which can pass to the pelvic cavity and make a "pedunculated uterine fibroma" within pelvic cavity.
3. Submucosal fibroids grow into the endometrial cavity; they are the least common, but the most significant type due to causing more symptoms and infertility.

Myomas can be found either solitary or multiple, ranging in size and location (19). As a result, regarding the symptoms, they differ from being asymptomatic to having severe symptoms such as infertility. The usual manifestations of

myomas entail abnormal uterine bleeding, pelvic pressure or pain, constipation, and urinary symptoms (3,18-20,23-26). Infertility may occasionally be observed, which is most often caused by submucosal fibroids. Furthermore, recurrent miscarriages are shown to be relevant to uterine fibroids (19, 27, 28).

Additionally, some researchers indicated that the probability of the *in vitro* fertilization failure or pregnancy loss in the patients with distorted endometrium due to myomas, increases up to 50% (19). Therefore, the accurate investigation of fibromas prior to infertility treatment is essential. The treatment choices vary from expectant management to medical and surgical therapy (e.g., myomectomy or hysterectomy), depending on the patient's age, symptoms, and reproductive expectation (3,19,29,30). The recurrency may happen; nevertheless, the likelihood of malignancy is rare (19).

TVS and transabdominal sonography (TAS) are the primary imaging methods used in the investigation of female pelvis, and the technique of choice in the evaluation of uterine myomas (1, 3, 19). In experienced hands, the sonographic examination facilitates the detection of the amounts, types, location, and size of the fibromas as well as the amount of endometrial distortion due to myomas, which is very important in the infertility workup. Therefore, these points should be considered in sonography reports. It's worth noting that in case of small fibromas of less than 5 mm in diameter or in obese patients, the TVS would be more accurate and sensitive than the TAS.

In case of submucosal fibroid and suspected endometrial distortion, it may be difficult to differentiate myoma from polyp. Consequently, further imaging modalities, such as sonohysterography or three-dimensional (3D) sonography, are required for detailed investigation. The endometrial thickness has a vital role in the accurate investigation of myomas by 3D TVS. The optimum timing of sonographic assessment of myomas in this situation is when the endometrium is more than 5 mm in diameter (1, 18, 19).

Endometrial Hyperplasia

Endometrial hyperplasia is defined as an abnormal proliferation of endometrial glands of

various size and shape, which results in thickened endometrium (15, 31-34). It occurs following the excess unopposed estrogen stimulation of any source (31, 33). Polycystic ovarian syndrome patients are more likely to have hyperplasia due to higher circulating estrogen levels. Therefore, a careful endometrial measurement should be performed in this group during the infertility workup. Endometrial hyperplasia is suspected in women presenting with heavy, prolonged, frequent, and irregular uterine bleeding (31-35).

When evaluating these patients by TA/TV sonography, we should note that the endometrial thickness and appearance change cyclically due to different phases of menstrual cycle. Therefore, we should ask about the day of the cycle in which the sonography examination was performed. Endometrial hyperplasia will be detected if the endometrial thickness measures ≥ 8 mm during the proliferative phase, ≥ 16 mm during the secretory phase, and ≥ 5 mm during the menopause (35-39).

Intrauterine Adhesions

Intrauterine adhesion (uterine synechiae, IUAs) is described as the presence of fibrotic tissue within the endometrial cavity, which causes intracavitary adhesions (1, 40-42). It is an acquired condition resulted from trauma to the basal layer of the endometrium usually following curettage or infection. Adhesions range from minor synechiae to severe cohesive adhesions (Asherman's Syndrome) (1, 40-45). The most common complications associated with IUA are amenorrhea, infertility, recurrent abortions, and preterm birth (45, 46).

IUA is detected by sonography when the endometrium is thin and irregular (1). However, the experts believe that TVS has limited use in confirming adhesions (47, 48). Extra imaging by means of hysterosonography may be helpful in this regard (47). To confirm the diagnosis, the endometrium needs to be assessed after taking preoperative exogenous estrogen for 4-8 weeks to measure maximal endometrial thickness (47-49).

Adenomyosis

Adenomyosis is a common benign condition in which ectopic endometrial glands grow into the uterine myometrium (3, 36, 50). As a result,

myometrial hypertrophy is associated with this disorder (48). It often occurs in the multiparous women. There are several possible risk factors for this condition including uterine trauma, abortion, chronic endometritis, and hyperestrogenism. The clinical manifestations of adenomyosis are pelvic pain, dysmenorrhea, menorrhagia, menometrorrhagia, uterine tenderness and enlargement, as well as infertility (36, 50).

The TVS is the first step imaging modality for the evaluation of the women suspected to have adenomyosis. Accordingly, several studies have indicated that TVS has a high sensitivity and accuracy in the diagnosis of adenomyosis, compared to the magnetic resonance imaging (MRI). However, TVS is a skill-dependent tool and the final diagnosis may need to be confirmed by MRI in cases that are uncertain (50). Adenomyosis should be considered if the following phrases are reported by the sonographer: 1) A normal-sized or enlarged globular shaped uterus, 2) A heterogeneous mottled texture of the myometrium, 3) "Swiss cheese appearance" due to blood clots within the myometrium, 4) Indistinct endometrial line due to disrupted border between the endometrium and myometrium (36, 50).

Congenital Anomalies

Uterine malformations are a various group of congenital uterine anatomic abnormalities originated from the development defect of müllerian ducts during fetal development (51-53). They are associated with higher incidences of infertility, recurrent abortions, intrauterine fetal death, intrauterine growth retardation, premature delivery, fetal malposition, caesarean section, retained placenta (51-55), and such gynecological complications as hematocolpos and hematometra (54). Uterine anomalies are detected in approximately 1-3% of all women (51); however, 10-25% of the women seek infertility workup (52).

According to the American Fertility Society classification, these malformations are classified into seven categories as follows (51, 52, 54): class I includes uterine hypoplasia and agenesis; class II contains unicornuate uterus; class III entails uterus didelphys; class IV consists of bicornuate uterus; class V is septate uterus; class VI includes arcuate uterus; and class VII entails the diethylstilbestrol-related anomalies (52-54).

During the sixth week of gestation, the uterus, cervix, and uterine tubes are developed from a pair of müllerian ducts (paramesonephric), which is associated with the improvement of three phases, namely organogenesis, fusion, and septal resorption (51, 54). In the organogenesis phase, the constitution of both müllerian ducts occurs and a failure in this regard results in uterine agenesis/hypoplasia or a unicornuate uterus. The fusion phase is described as the fusion of the ducts to constitute the uterus and any defect in this phase leads to a bicornuate or didelphys uterus. The final phase is characterized as the further resorption of the central septum once the ducts have been fused. If there is any deficiency in this stage, a septate uterus will be the result (51, 53). The accurate diagnosis of uterine abnormalities is crucial because the treatment procedures and pregnancy outcomes differ between the various classes of malformations (52).

Sonography, in combination with hysterosalpingography, has an important role in the investigation and classification of the uterine anomalies. In case of no clinical doubt regarding the tubal disorders, TVS can be applied as a more tolerable and less invasive imaging modality. The combination of 3D techniques with TVS gives the specialist the opportunity to investigate the coronal view of the uterus, which configures both endometrium and myometrium together for more accurate diagnosis.

We should note that the optimum timing of ultrasound evaluation and the classification of anatomical uterine disorders are "the secretory phases of menstrual cycle" when the endometrial thickness and echo pattern are better characterized (1, 53-55). These anomalies are evaluated at days 11-14 and 17-21 in routine 2D ultrasound scan of the pelvis and 3D/4D sonography, respectively.

Discussion

According to the findings of the reviewed articles, uterine polyps are best distinguished during days 4-6 of the menstrual cycle. Endometrial distortion caused by uterine fibromas is well-assessed on days 11-14 and 17-21 on 2D and 4D ultrasound imaging. Endometrial hyperplasia is best recognized at proliferative phase. Furthermore, the congenital malformations of the uterus are best evaluated during days 11-14

and 17-21 on 2D and 4D sonography, respectively. In addition, IUA should be diagnosed by serial ultrasound scans. Considering these points is crucial for referring the infertile patients for ultrasonography.

Conclusion

Sonography is an accurate, non-invasive, and cost-effective imaging modality for examining the infertile women. It usually provides beneficial information about the uterine disorders, which cause female infertility. Therefore, every midwife needs to learn about the application of this diagnostic imaging technique. It is worth noting that the pelvic organs are affected by cyclic changes during the menstrual cycle and hormone therapy. Regarding this, the pathologic conditions of pelvis need to be well-assessed depending on the day of the menstrual cycle. Therefore, the optimal timing of the ultrasound scan is the key point for the diagnosis and decision making about these patients.

To the extent of the researchers' knowledge, no article has investigated the female infertility diagnosis by ultrasound for midwives. This article would be a helpful reference for the midwives working in the field of infertility and all medical students who are interested in this area.

Acknowledgements

Hereby, we would like to express our gratitude to the staff of the sonography unit at the Reproductive Imaging Department of Royan Institute for their warm cooperation. We are grateful to Zahra Arianfar and Mansoureh Soleimani in particular. We specially thank Narges Bagheri Lankarani (PhD) for her worthy comments regarding the article revision.

Conflicts of interest

The authors declare no conflicts of interest.

References

1. Fleischer A, Toy E, Lee W, Manning F, Romero R. Sonography in obstetrics and gynecology. 7th ed. San Juan: McGraw-Hill; 2011.
2. Rumack CM, Wilson SR, Charboneau JW. Diagnostic ultrasound. London: Mosby; 4th ed, 2011.
3. Novak E. Berek & Novak's gynecology. 14th ed. Philadelphia: Lippincott Williams & Wilkins; 2007.
4. Irani S, Javam M, Ahmadi F. Sonographic assessment of female infertility: instruction for midwives and nurses. International Journal of Fertility and Sterility. 2014; 8(Supp 1):280.
5. Singh K, Malhotra N. Step by step ultrasound in infertility. New York: McGraw-Hill; 2004.
6. Derchi LE, Serafini G, Gandolfo N, Gandolfo NG, Martinoli C. Ultrasound in gynecology. European Radiology. 2001; 11(11):2137-2155.
7. Irani S, Ahmadi F, Javam M. Application of sonography in infertility treatment cycles: instructions for midwives and nurses. Iranian Journal of Reproductive Medicine. 2015; 1(2):36.
8. Irani S, Javam M, Ahmadi F. Correct scan, for the correct patient, at the correct time: a guideline for sonographic evaluation of the infertility for midwives and nurses. Iranian Journal of Reproductive Medicine. 2014; 12(Suppl 1):127.
9. Hackeloer BJ. The role of ultrasound in female infertility management. Ultrasound in Medicine & Biology. 1984; 10(1):35-50.
10. Hrehorcak M, Nargund G. "One-Stop" fertility assessment using advanced ultrasound technology. Facts, Views & Vision in ObGyn. 2011; 3(1):8-12.
11. Salim S, Won H, Nesbitt-Hawes E, Campbell N, Abbott J. Diagnosis and management of endometrial polyps: a critical review of the literature. Journal of Minimally Invasive Gynecology. 2011; 18(5):569-581.
12. Berridge DL, Winter TC. Saline infusion sonohysterography. Journal of Ultrasound in Medicine. 2004; 23(1):97-112.
13. Macthinger R, Korach J, Padoa A, Fridman E, Zolti M, Segal J, et al. Transvaginal ultrasound and diagnostic hysteroscopy as a predictor of endometrial polyps: risk factors for premalignancy and malignancy. International Journal of Gynecological Cancer. 2005; 15(2):325-328.
14. Sharma M, Taylor A, Magos A. Management of endometrial polyps: a clinical review. Reviews in Gynaecological Practice. 2004; 4(1):1-6.
15. Davis PC, O'Neill MJ, Yoder IC, Lee SI, Mueller PR. Sonohysterographic findings of endometrial and subendometrial conditions. Radiographics. 2002; 22(4):803-16.
16. Bettocchi S, Achillarre MT, Ceci O, Luigi S. Fertility-enhancing hysteroscopic surgery. In Seminars in Reproductive Medicine. 2011; 29(2):75-82.
17. Jorizzo JR, Chen MY, Riccio GJ. Endometrial polyps: sonohysterographic evaluation. American Journal of Roentgenology. 2001; 176(3):617-621.
18. Wilde S, Scott-Barrett S. Radiological appearances of uterine fibroids. Indian Journal of Radiology and Imaging. 2009; 19(3):222-231.
19. Wallach EE, Vlahos NF. Uterine myomas: an overview of development, clinical features, and management. Obstetrics and Gynecology. 2004; 104(2):393-406.

20. Parker WH. Etiology, symptomatology, and diagnosis of uterine myomas. *Fertility and Sterility*. 2007; 87(4):725-736.
21. Baird DD, Dunson DB, Hill MC, Cousins D, Schectman JM. High cumulative incidence of uterine leiomyoma in black and white women: ultrasound evidence. *American Journal of Obstetrics and Gynecology*. 2003; 188(1):100-107.
22. Fielding JR, Brown DL, Thurmond AS. *Gynecologic imaging: expert radiology series*. Philadelphia: Elsevier Health Sciences; 2011.
23. Murase E, Siegelman ES, Outwater EK, Perez-Jaffe LA, Tureck RW. Uterine leiomyomas: histopathologic features, MR imaging findings, differential diagnosis and treatment. *Radiographics*. 1999; 19(5):1179-1197.
24. Hutchins Jr F. Uterine fibroids. Diagnosis and indications for treatment. *Obstetrics and Gynecology Clinics of North America*. 1995; 22(4):659-665.
25. Coronado GD, Marshall LM, Schwartz SM. Complications in pregnancy, labor, delivery with uterine leiomyomas: a population-based study. *Obstetrics and Gynecology*. 2000; 95(5):764-769.
26. Lippman SA, Warner M, Samuels S, Olive D, Vercellini P, Eskenazi B. Uterine fibroids and gynecologic pain symptoms in a population-based study. *Fertility and Sterility*. 2003; 80(6):1488-1494.
27. Propst AM, Hill JA. Anatomic factors associated with recurrent pregnancy loss. *In Seminars in Reproductive Medicine*. 2000; 18(4):341-350.
28. Benson CB, Chow JS, Chang-Lee W, Hill JA, Doubilet PM. Outcome of pregnancies in women with uterine leiomyomas identified by sonography in the first trimester. *Journal of Clinical Ultrasound*. 2001; 29(5):261-264.
29. Lefebvre G, Vilos G, Allaire C, Jeffrey J, Arneja J, Birch C, et al. The management of uterine leiomyomas. *Journal of Obstetrics and Gynaecology Canada*. 2003; 25(5):396-418.
30. Fernandez H, Sefrioui O, Virelizier C, Gervaise A, Gomel V, Frydman R. Hysteroscopic resection of submucosal myomas in patients with infertility. *Human Reproduction*. 2001; 16(7):1489-1492.
31. Hannemann MM, Alexander HM, Cope N, Acheson NJ, Phillips A. Endometrial hyperplasia: a clinician's review. *Obstetrics, Gynaecology & Reproductive Medicine*. 2010; 20(4):116-120.
32. Afzal S, Haroon F. Endometrial hyperplasia mimicking as aggressive endometrial carcinoma on imaging: role of diffusion weighted MRI. *Pakistan Journal of Radiology*. 2009; 19(4):127-130.
33. Brun JL, Descat E, Boubli B, Dallay D. Endometrial hyperplasia: a review. *Journal de Gynecologie, Obstetrique et Biologie de la Reproduction*. 2006; 35(6):542-550.
34. Nalaboff KM, Pellerito JS, Ben-Levi E. Imaging the endometrium: disease and normal variants. *Radiographics*. 2001; 21(6):1409-1424.
35. Montgomery BE, Daum GS, Dunton CJ. Endometrial hyperplasia: a review. *Obstetrical & Gynecological Survey*. 2004; 59(5):368-378.
36. Kurjak A, Arenas JB. *Donald school textbook of transvaginal sonography*. New Delhi, India: Jaypee Brothers Medical Publishes; 2005.
37. Rumack CM, Wilson SR, Charboneau JW. *Diagnostic ultrasound*. London: Mosby; 2005.
38. Callen PW. *Ultrasonography in obstetrics and gynecology*. Philadelphia: Saunders; 2008.
39. Hricak H, Akin O, Sala E, Ascher S, Levine D, Reinhold C. *Diagnostic imaging: gynecology*. Salt Lake city, Canada: AMYRSIS; 2007.
40. Heinonen PK. Intrauterine adhesions--Asherman's syndrome. *Duodecim*. 2009; 126(21):2486-2491.
41. March CM. Asherman's syndrome. *In Seminars in Reproductive Medicine*. 2011; 29(2):83-94.
42. Yu D, Wong YM, Cheong Y, Xia E, Li TC. Asherman syndrome--one century later. *Fertility and Sterility*. 2008; 89(4):759-779.
43. Tan I, Robertson M. The role of imaging in the investigation of Asherman's syndrome. *Australasian Journal of Ultrasound in Medicine*. 2011; 14(3):15-18.
44. Feigin K, Rosenblatt R, Kutcher R, Papanicolaou N. Sonohysterography in the evaluation of infertility. *Applied Radiology*. 2000; 29(1):14-19.
45. Ahmadi F, Javam M. Role of 3D sonohysterography in the investigation of uterine synechiae/asherman's syndrome: pictorial assay. *Journal of Medical Imaging and Radiation Oncology*. 2014; 58(2):199-202.
46. Dawood A, Al-Talib A, Tulandi T. Predisposing factors and treatment outcome of different stages of intrauterine adhesions. *Journal of Obstetrics and Gynaecology Canada*. 2010; 32(8):767-770.
47. Deans R, Abbott J. Review of intrauterine adhesions. *Journal of Minimally Invasive Gynecology*. 2010; 17(5):555-569.
48. Magos A. Hysteroscopic treatment of Asherman's syndrome. *Reproductive Biomedicine Online*. 2002; 4(3):46-51.
49. Myers EM, Hurst BS. Comprehensive management of severe Asherman syndrome and amenorrhoea. *Fertility and Sterility*. 2012; 97(1):160-164.
50. Hulka CA, Hall DA, McCarthy K, Simeone J. Sonographic findings in patients with adenomyosis: can sonography assist in predicting extent of disease? *American Journal of Roentgenology*. 2002; 179(2):379-383.
51. Chandler TM, Machan LS, Cooperberg PL, Harris AC, Chang SD. Müllerian duct anomalies: from diagnosis to intervention. *The British Journal of Radiology*. 2014; 82(984):1034-1042.
52. Ahmadi F, Rashidi Z, Javam M. *Diagnosis of Congenital uterine malformations*. 1st ed. Tehran,

- Iran: Publication of Royan Institute; 2016. P. 148 (Persian).
53. Javam M, Ahmadi F. Congenital uterine malformations: a widespread phenomenon among infertile women with recurrent miscarriages and IVF failure. *Iranian Journal of Reproductive Medicine*. 2015; 13(Suppl 1):53.
54. Ahmadi F, Haghghi H. Detection of congenital mullerian anomalies by real-time 3D sonography. *Journal of Reproduction and Infertility*. 2012; 13(1):65-66.
55. Moini A, Mohammadi S, Hosseini R, Eslami B, Ahmadi F. Accuracy of 3-dimensional sonography for diagnosis and classification of congenital uterine anomalies. *Journal of Ultrasound in Medicine*. 2013; 32(6):923-927.